

Fractures of the Femoral Neck

Zlomeniny krčku femuru

T. LEIN, P. BULA, J. JEFFRIES, K. ENGLER, F. BONNAIRE

Department of Trauma-, Reconstructive- and Hand-Surgery,
Hospital Dresden-Friedrichstadt, Academic Teaching Hospital of the Technical University Dresden,
Dresden, Germany

SUMMARY

The ideal treatment of the intracapsular fracture of the femoral neck still is subject of discussion. The demographic development of the population in Europe with fractures of the neck of femur being typical in the older patient, requires conclusive and stringent concepts of treatment. Adequate and patient oriented therapy should be promoted, regional differences and provisional deficiencies need to be adjusted in order to minimize the rate of complications. The guideline "Schenkelhalsfraktur" of the German board of trauma surgeons, the 'Deutsche Gesellschaft für Unfallchirurgie', and the article at hand are meant to serve as a manual for the trauma surgeon. Based on evaluated data it simplifies rational decision-making for treatment of fractures of the proximal femur. Moreover, secondary prophylaxis as well as the subsequent outpatient treatment and the social reintegration of the patients recovering from fractures of the femoral neck remains vitally important. After all, even with ideal treatment of the fracture more than half of the patients are impaired for a long time and one out of four permanently depends on nursing assistance.

INTRODUCTION

Fractures of the femoral neck are intracapsular injuries and therefore entail the risks of posttraumatic arthrosis, avascular necrosis of the head of femur and eventually the loss of the joint due to implantation of an alloarthroplasty.

The fracture of the femoral neck is a common event that usually affects the older patient with accompanying osteoporosis after a trivial trauma. The increased number of fractures of the femoral neck is essentially due to the demographic progress with increasing life expectancy in industrial countries. These injuries demand conclusive concepts of treatment by the attending surgeon depending on whether the aim is to preserve the hip joint with good results and pleasant function or whether preference must be given to hip joint replacement. The presentation at hand intends to help to get a differentiated point of view of fractures of the femoral neck as well as to provide stringent therapy for fractures of the hip joint.

FRACTURES OF THE FEMORAL NECK

Classification of the fractures of the femoral neck

Any sensible classification of the fractures of the femoral neck must include criteria that are crucial to determining the treatment of these fractures. The classification by Garden has proven helpful when deciding on osteosynthesis versus endoprosthesis (image 1a, b).

This classification differentiates the valgus impacted types (type I), the undisplaced, nonimpacted types (type II) from the dislocated fractures, where the x-ray shows contact between the trabecular and the cortical structures at the Adam's arc (type III). In this type, the axial x-ray depicts a perfectly continuous cortical bone line from the dorsal part of the head of femur to the convex arc at the dorsal femoral neck. This implies that the so-called Weitbrecht ligament which conjoins the dorsal structures as part of the capsule is not yet torn. A successful reduction of these fractures is considerably more promising as opposed to those fractures with

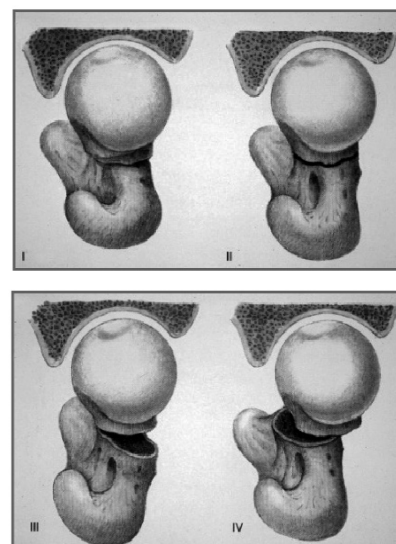


Image 1a–b. Classification by Garden of the fractures of the femoral neck.

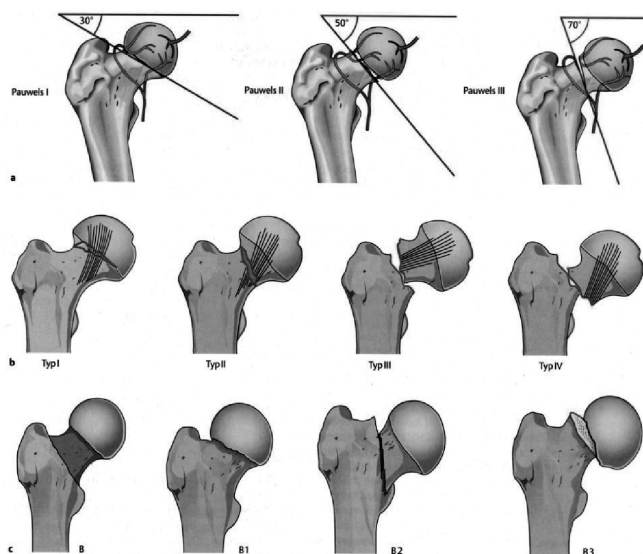


Image 2. Classification of the fractures of the femoral neck by Pauwels, Garden and AO.

complete displacement of the fragment which is always combined with a torn Weitbrecht ligament (type IV). With the latter fractures not only the reduction is more difficult, but also the risk for a necrosis of the head of femur and for a mechanical complication such as secondary redislocation or forming of pseudoarthrosis increases.

Another common classification is the one by Pauwels originating from 1951 (image 2). The Pauwels classification is primarily based on the stability of the fracture. Type I describes a valgus impaction of the head of femur, an in itself stable fracture. Yet, biological processes of absorption of the bone structure can turn a stable into an unstable situation and consequently lead to secondary dislocation of the head of femur. A Type II fracture by Pauwels describes an oblique fracture line in the anterior posterior plane with angulation of the plane of the fracture between 30° to 50°. These fractures are unstable, at the same time the oblique fracture line provides more stability with osteosynthesis than Pauwels III fractures. Pauwels III fractures show an angulation of the fractured planes up to 90° to the horizontal in the anterior posterior plane. In these fractures, the cranial fracture line always ends in the transition zone between the cartilage part of the femoral head and the cranial onset of the femoral neck. They often lead to impairment of the epiphyseal vessels, that enter the femoral head at the same spot, are highly unstable and very difficult to reduce. The disadvantage of Pauwels classification is the disregard of the angulation of the fracture in the axial plane. Quite often the fracture line runs oblique in the axial plane as well, hence an exact assessment is impossible.

In addition to the already named criteria of the displacement of the fracture and the course of the fracture line, the AO classification (32) differentiates the so-called subcapital fractures. These are shearing fractures with high instability and bad prognosis regarding the vitality of the head of femur (image 2). Eventually all

the aspects of the three types of classification named above serve as decision guidance for choosing either osteosynthesis or prosthetic treatment.

Influence of the time to treatment on the preservation of the head of femur

Fractures of the femoral neck in the young patient should be considered as absolute priority for a rapid operative intervention with the aim of preserving the head of femur (8). But even with an all in all greater risk of mortality, older patients may also benefit from immediate surgery if preservation of the hip joint is considered (24, 25). A workgroup in Hungary intensively dealt with the problem of the fractures of the femoral neck and their surgical treatment. Manninger et al. studied the course of 740 patients that underwent surgical treatment in the Central Research Institute of Budapest between 1972 and 1977. They arrived at the conclusion that avascular necrosis of the head of femur can be significantly reduced ($p < 0,001$) when surgical treatment with reduction and fixation of the displaced fracture is performed within six hours after the accident. An obvious correlation and an increase of the complication rates as results of a belated procedure (time to surgery > 6 h) could be proved. These complications include a remarkable increase of both early and late necrosis of the head of femur even after three to six years after the accident (31). Meanwhile other studies also confirm the advantages of an early surgical intervention with head preserving surgery of the hip joint (22, 23).

Technique of the reposition to maintain the head of femur

Garden and Barnes were the first to prove, that reduction and position of the implant are crucial for the long-term result of the osteosynthesis (3). This applies to the early onset complications like secondary dislocation and healing deficits ("non-union") as well as to the late onset complications such as posttraumatic arthrosis and partial collapse of the head of femur ("late collapse"). A valgus deformation of more than 10° is clearly associated with a higher rate of necrosis of the femoral head. Garden explains the latter phenomenon with the resulting incongruence of the joint followed by subluxation of the head of femur out of the acetabulum (19). Valgus deformation provides more stability in a reduced and surgi-

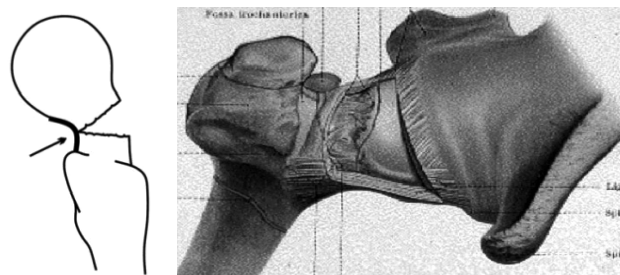
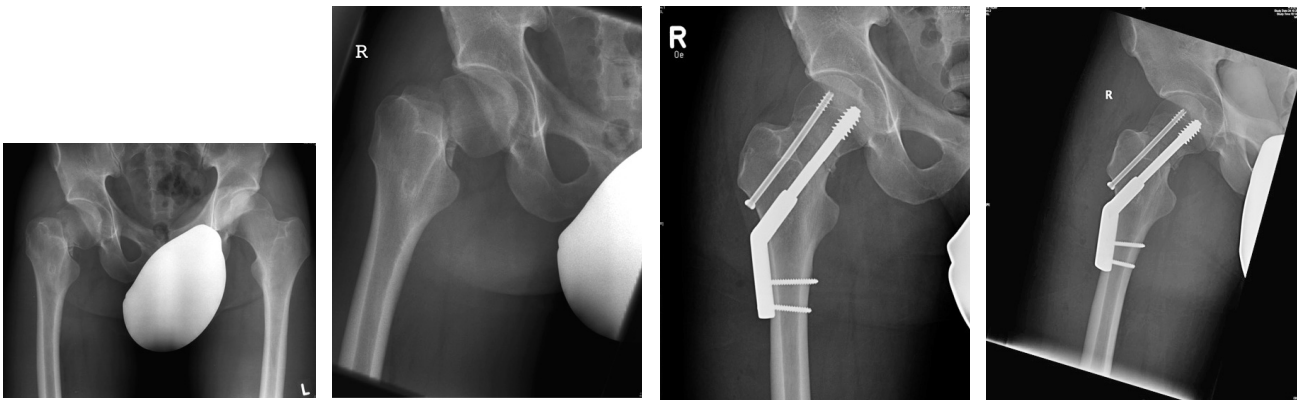


Image 3a-b. With maintenance of the Weitbrecht ligament an anatomic reposition of the Garden III fracture is possible (a); dorsal capsule as reposition counterfort (b).



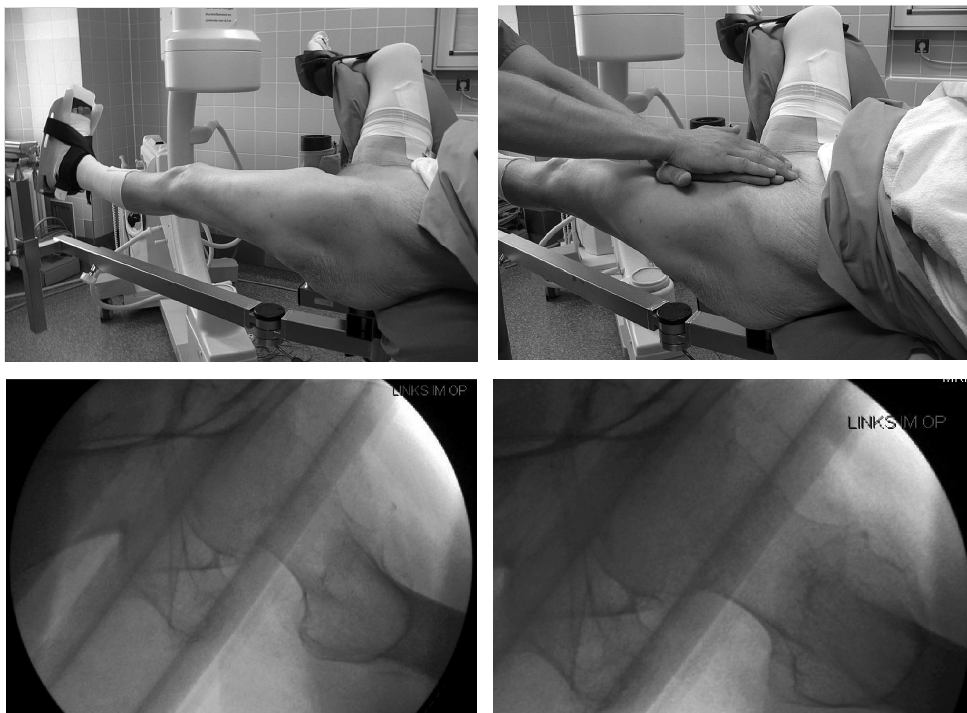
a | b | c | d
e | f

Image 4a–f. Documentation of the course of a Garden IV fracture and osteosynthesis with dynamic hip screw (DHS) and antirotation screw (ARS). Display of a Garden IV fracture of a twenty-eight-year-old man after bike accident in the anterior posterior and in the Lauenstein recording (a, b). Immediate supply four hours after accident with anatomic reposition. Osteosynthesis with dynamic hip screw (DHS) and antirotation screw (c, d). Healing up of the fracture with slight shortening of the femoral neck. Documentation after removal of material two years after osteosynthesis (e, f).

cally treated fracture of the femoral neck. Therefore surgeons appreciated that circumstance whereby the obvious disadvantages were accepted (26).

But a non-anatomic reduction always results in an incongruence of the joint and subsequently can lead to a healing deficit of the fracture. For that reason an anatomic reposition is not only more logical but also prac-

ticable due to current implants and imaging during the surgery. After reduction the fracture has to show proper alignment in both planes. The fracture of the femoral neck originates from direct trauma to the trochanter major and always holds a vector directed from dorsal to ventral. In the chain of events at first the dorsal parts of the femoral neck are impacted, secondly the ventral part



a | b
c | d

Image 5a–d. Reduction of a dislocated fracture of the femoral neck. Withdrawal using the traction table via lengthwise traction and internal rotation, if necessary slight abduction (a); via manual pressure from ventral the Weitbrecht ligament is stretched out (b); the initial retroversion torsion of the fragments of the head and shortening of the femoral neck is being neutralized via pressure on the groin, leading to anatomic conditions (c, d).

of the fracture opens up, followed by increasing outward rotation of the injured leg and finally translation and dislocation with shortening of the injured leg. These mechanisms must be performed in reverse in order to reduce the fracture. For the valgus impacted fracture a slight adduction of the leg combined with a ventral compression restores the anatomy, for varus impacted fracture it is abduction in combination with compression from ventral. According to its definition, a non-dislocated fracture does not require reduction.

Garden III fractures need proper correction of the length and rotation combined with compression from ventral to dorsal. The preserved Weitbrecht ligament simplifies the reduction as it provides a counterpart to the compression from ventral (image 3a, b).

The Garden IV type lacks this ligament and consequently the counterpart. This circumstance can immensely hinder the reduction of the fracture, nevertheless a reposition can be successful especially with new fractures (image 4).

Reduction can be performed with or without using a traction table. To simplify matters and for economic reasons (saving an assistant) reduction can be safely handled using the traction table without rough maneuvers of extension or rotation. The procedure is controlled via x-ray imager. It is important to depict both planes as well as the adjustment while applying ventral compression (image 5a–d). This compression has to be maintained until temporary retention of the head fragment is achieved. In order to ensure rotation stability of the head fragment, the retention is preferably performed with at least three Kirschner wires (image 6).

Choice of implant

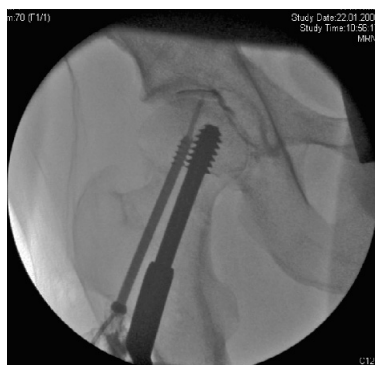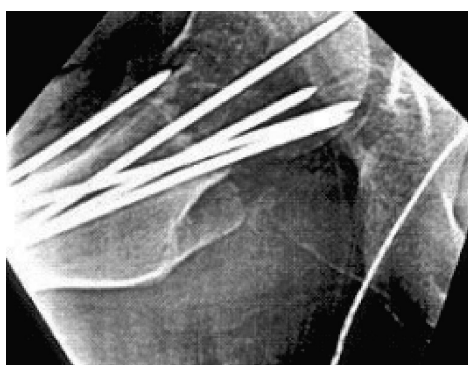In all relevant literature no specific implant design shows significantly better results. Parker points out the role of proper reduction as well as operating experience with the implant (35). Particularly in the older patient, the dynamic hip screw (DHS) over the past years has achieved more and more acceptance in the European and Anglo-American world as opposed to using three cannulated screws (29). The superiority of this implant can be deduced from biomechanical analysis, showing that in case of proper reduction of the fracture this implant allows immediate full weight bearing without any risk of early dislocation (6). This construct becomes

even more stable when an additional screw is placed cranial of the dynamic hip screw, serving as anti rotation screw. The feared higher risk for necrosis of the femoral head could not be confirmed. Therefore, using greater diameters for screw osteosynthesis is recommended as well (27). Besides the great primary stability, the major advantage of the dynamic hip screw (DHS) is the easy to place single leading wire which has to be situated correctly in each plane as opposed to the three leading wires when using cannulated screws. The latter can only very rarely be placed in parallel direction in every plane (21). In practise those screws often converge or diverge and consequently lose mechanical grip and rotation stability (21). Furthermore “simple screws” lack the locking plate feature with the plate including a sliding sleeve fixed to the diaphysis of the bone, preventing varus displacement of the fracture, especially in osteoporotic bone (40).

Beyond doubt a great primary stability promotes revascularization of the head fragment in case of impaired perfusion (6). Intramedullary implants additionally peril the femoral heads perfusion and pose a risk for reperfusion based on its greater volume at the proximal end. Therefore intramedullary implants are obsolete for the treatment of fractures of the femoral neck. In addition to that, in contrast to usage for pertrochanteric fractures of the femur, intramedullary implants do not provide better mechanical resilience for intracapsular fractures (35).

Intracapsular hematoma

The hematoma caused by the fracture empties into the capsule via the fracture gap. The increasing intracapsular pressure has been held responsible for additional impairment of perfusion of the femoral neck, similar to a compartment syndrome. There is no prospective randomized study that in similar fracture types shows a positive correlation between that origin of necrosis of the femoral head and either surgical decompression of the hematoma or leaving the hematoma untreated. Too many single factors play a role. Examination results show a decrease of appearance of aseptic necrosis of the femoral head when capsulotomy is performed, especially in children (11, 14). Intraarticular pressure measurements executed during surgery while in the process of reduction (traction and inner rotation) show significant



6 | 7

Image 6. To obtain an anatomic protection from reposition and rotation, it is often necessary to use at least three Kirschner wires for instable fractures.

Image 7. Evidence of easing the hematoma via the cannulated femoral neck screw after the guide wire has been driven into the joint.

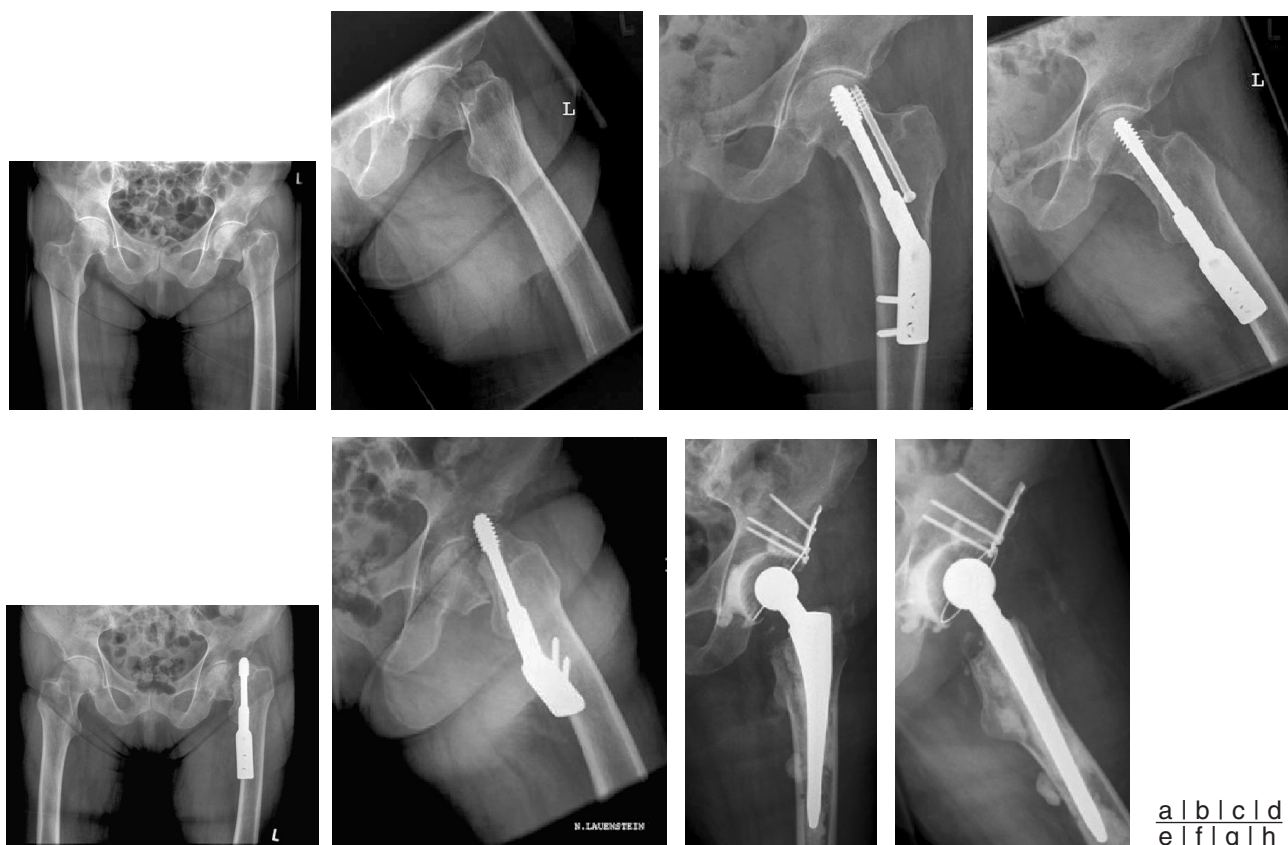

Image 8a–h. Consequences of a false positioning of an implant at the femoral neck. Treatment of a Garden IV fracture of a sixty-three-year-old female patient. With an acceptable reposition the postoperative x-ray images show a too cranial position of the femoral neck component (a, b, c, d); consecutively after bearing weight, cutting out of the components as well as arrosion of the acetabulum occurs (e, f); after removing the metal the revision includes the implantation of a cemented total endoprosthesis with a Harris-acetabuloplasty (g, h).

increase of pressure with pressure values that must affect the femoral head perfusion via the intraarticular vessels of the epiphysis (9). Decompression therefore seems sensible. However, fenestration of the capsule implicates a considerable extension of the primarily closed intervention. We thus invented a simple but safe method by driving the leading wire into the joint and then decompress and irrigate the joint via the cannulated femoral neck screw. This technique enables a gentle decompression of the hematoma without expanding the surgery (image 7).

Complication management

When proper and promising reduction cannot be achieved in a closed state of the fracture, but preservation of the hip joint has priority, open reduction may be reasonable. In older patients switching to endoprosthetic treatment is recommended. For this purpose, the wound has to be closed and the patient has to be transferred from traction to a normal table. Then the already existing access has to be extended to an approach by Bauer in order to expose the hip joint and implant an endoprosthesis. Difficulties regarding reduction are not expected in Garden I to III fractures.

When displacement of a fracture occurs in conservatively treated fractures, the only sensible treatment is implantation of an endoprosthesis, since in those cases there is a particularly high risk of complication after late osteosynthesis (5).

The typical complication of the osteosynthetically treated fracture of the femoral neck is the early redisplacement of the fracture. In most cases this is the result of either improper anatomical reduction or of a suboptimal placement of the implant or respectively of the wrong length of the implant (image 8a–h).

When the result of the initial reduction, the choice of implant, the placement and the length of the implant is impeccable, any reosteosynthesis including change over of the implant (e. g. dynamic hip screws (DHS) or additional intertrochanteric osteotomy) is only legitimate for the young patient (image 9). Reasons for reosteosynthesis in the young patient are the greater chance of acquiring sufficient stability as well as the beneficial effects on the long term results in case of proper healing. An older patient on the contrary should preferably be treated with an endoprosthesis with presumably no implant failure (30).

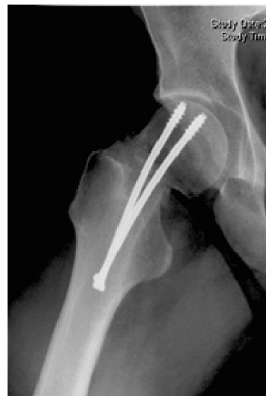
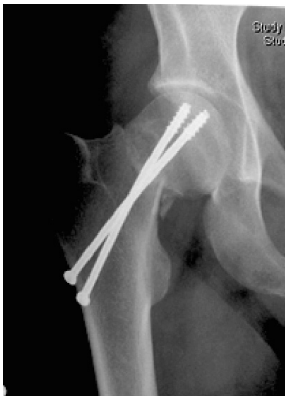
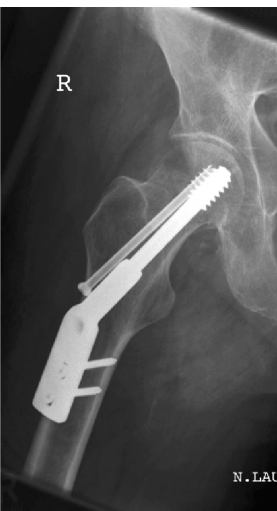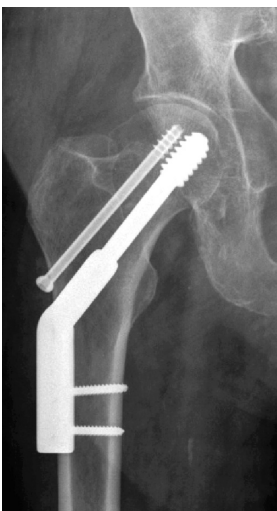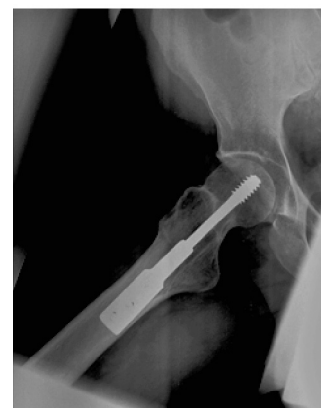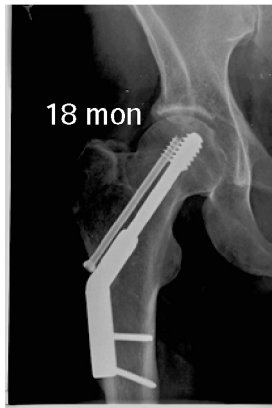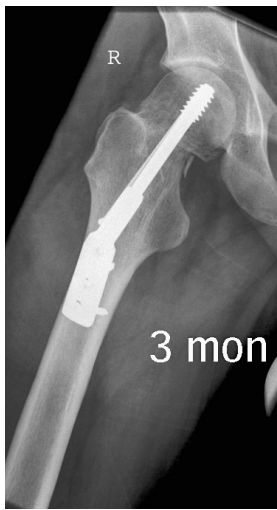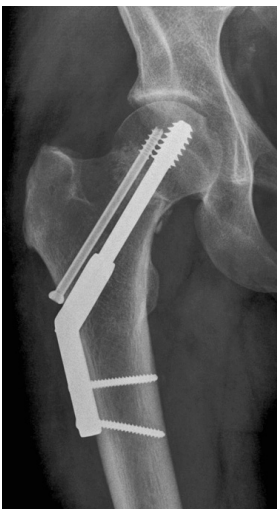Image 9a-f. Thirty-nine-year-old male patient, provided with an osteosynthesis with screws in another hospital. The reposition succeeded only incompletely, an instability of the head-neck fragments remained (a, b); reosteosynthesis with dynamic hip screws (DHS) in our hospital four weeks after first surgery (c, d); controlling the course after eighteen months shows the healing up of the fracture without any indication for neither material easing nor for a necrosis of the head of femur (e, f).

a | b
c | d | e | f

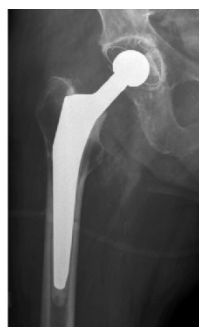
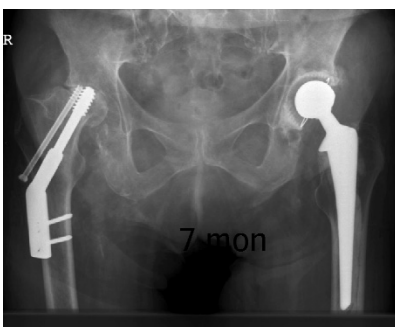
a

b

Other early complications include soft tissue hematoma, infection of the soft tissue and in rare cases also of the bone substance. These occur more seldom in patients treated with osteosynthesis compared to those treated with endoprosthesis. Treatment of infections involves an early and thorough revision with not only decompression of the hematoma but also debridement down to the implant. In addition it is reasonable to collect smears intraoperatively and make use of jet-lavage. A complication expected as soon as in the first year after the osteosynthesis is the so called 'early collapse' meaning a global necrosis of the femoral head. This complication is reported under 10% in the literature (12, 19). In these cases only an endoprosthesis can restore the function of the hip joint (image 10).

Non-union of the femoral neck manifests within the first twelve months after the osteosynthesis in most cases (35). This diagnosis often has to be confirmed by computed tomography. Another typical complication of the osteosynthesis is the shortening of the femoral neck in



c

d

Image 10a-d. Seventy-four-year-old female patient with „early collapse“. Osteosynthesis of a compressed Garden I fracture on the day of the accident (a, b); x-ray control because of afflications growing more severe after eight weeks: almost complete necrosis of the head of femur, arrosion of the acetabulum via the screws (c); result of the revision with implantation of a total endoprosthesis for the hip (d).

the process of union. It can limit the range of motion in the hip joint and lead to painful impingement (16). Surgical readjustment can be helpful in individual cases. Normally implantation of an endoprosthesis with reconstruction of the length, the offset and muscular tension is necessary.

The late onset necrosis ("late collapse") can occur as long as 7–10 years after osteosynthesis (1). It manifests as partial necrosis of the anterolateral surface of the head of femur. It may be treated conservatively, but also by drilling with or without implementation of bone grafts. Another option is the correctional osteotomy (valgizing or inflecting, rotation). All in all only about half of the patients require surgical treatment. Within the range of options, again a change over to an endoprosthesis comes last.

PROVISION WITH AN ENDOPROSTHESIS

The decision for treatment with an endoprosthetic device of a displaced fracture of the femoral neck comes easier in the older patients. This is especially true when the time to operation exceeds the favourable time limitation for promising results. Only in rare cases (e.g. high operative risk for an endoprosthesis) an osteosynthesis should be performed for a displaced fracture in the old patient later than 6 hours to the accident (28).

Regardless of that, all preoperative arrangements have to start immediately after common diagnostics and analgesia to avoid any delay of the surgery. This includes not only anesthetic consultation but where necessary other consultations and preparation for intensive care (see guidelines for the fracture of the head of femur of the German organization Deutsche Gesellschaft für Unfallchirurgie (DGU) (39). A delay of the operation to more than 24 hours after the fracture occurred poses the following disadvantages:

- greater morbidity and mortality (15),
- higher rate for the necrosis of the head of femur (7, 9, 19),
- the chances for a successful osteosynthesis and rehabilitation decrease (15),
- higher rate of bedsores (17),
- the incidence of vein thrombosis and pulmonary embolism increases with the preoperative holding time (36).

Total endoprosthesis versus bipolar prosthesis

The younger and the more physically active the affected patient is, the more he or she will profit from total endoprosthesis. This concerns the range of motion mainly, but also the pain level and the endurance of the prosthesis. Patients providing good bone quality can profit from a prosthesis without the use of cement, especially the bone-sparing short stem hip prosthesis. So far, there is no sufficient data on the experiences with minimally invasively implanted endoprosthesis for fractures of the femoral neck. The following aspects can help defining a differentiated indication:

There is no evidence for bipolar prosthesis being advantageous versus the unipolar prosthesis (10, 13). For implantation of a hemi prosthesis compared to total endoprosthesis, however, less surgery time is needed (about 6–18%) and therefore seems less stressful. In addition, the intraoperative loss of blood is significantly less, the early postoperative results are equal to those of total joint replacement and the rate of early revisions is lower (37). The hemi prosthesis entails an imminent risk of protrusion into the acetabulum, the risk is about four times higher than with a total endoprosthesis (2). On the other hand implantation of a total endoprosthesis involves a higher risk for luxation of the prosthesis (about 10–20%) (34). Three years after the implantation however, it shows better results than a hemi prosthesis (38). It also shows advantages concerning implantation after failed osteosynthesis compared to hemi prosthesis (33).

The preoperative planning for both types of prosthesis equals that for the elective procedure: according to the x-ray images of the deep adjusted pelvis as well as a Lauenstein or an axial projection, the gradient and the size of the socket as well as the thickness of the acetabulum, the center of the head of femur, the position of the trochanters, the diameter of the shaft of femur and the antecurvature of the femur can be measured. The head of femur of male patients is significantly bigger than that of female patients (4). Generating planning sketches is the best preparation for the operation and it helps to avoid serious misinterpretations (image 11).

Usually a once-only antibiotic prophylaxis with a cephalosporin of the second generation is administered (20). Thromboembolism prophylaxis begins preoperatively and is continued for five weeks postoperatively.

Position and access

For provision of the hip joint by endoprosthesis all the dominant standard approaches are suitable. The patient can be positioned either in supine position or in lateral decubitus position. Pressure exposed bony prominences have to be well padded. The use of x-ray imaging for intraoperative fluoroscopic control has proved of value in the daily routine. Positioning the patient on the carbon table may be simple, attaching any counterpart device though is fairly difficult. Furthermore non-slip mats may be useful at times.

The anterolateral approach by Watson-Jones and the lateral transmuscular approach by Bauer or Hardinge are well proven. In our own patient population we prefer the direct anterolateral access as described by Watson-Jones to access the hip joint for provision with bipolar prosthesis. In this approach an extensive exploration of the acetabulum is not necessary. The exact display of the acetabulum can be achieved using the lateral transmuscular access by Bauer, which we therefore prefer for the implantation of a total endoprosthesis. The posterior access by Kocher-Langenbeck is suitable for this purpose too, but the rates for luxation are higher. Appropriate measures to reconstruct the dorsal parts of

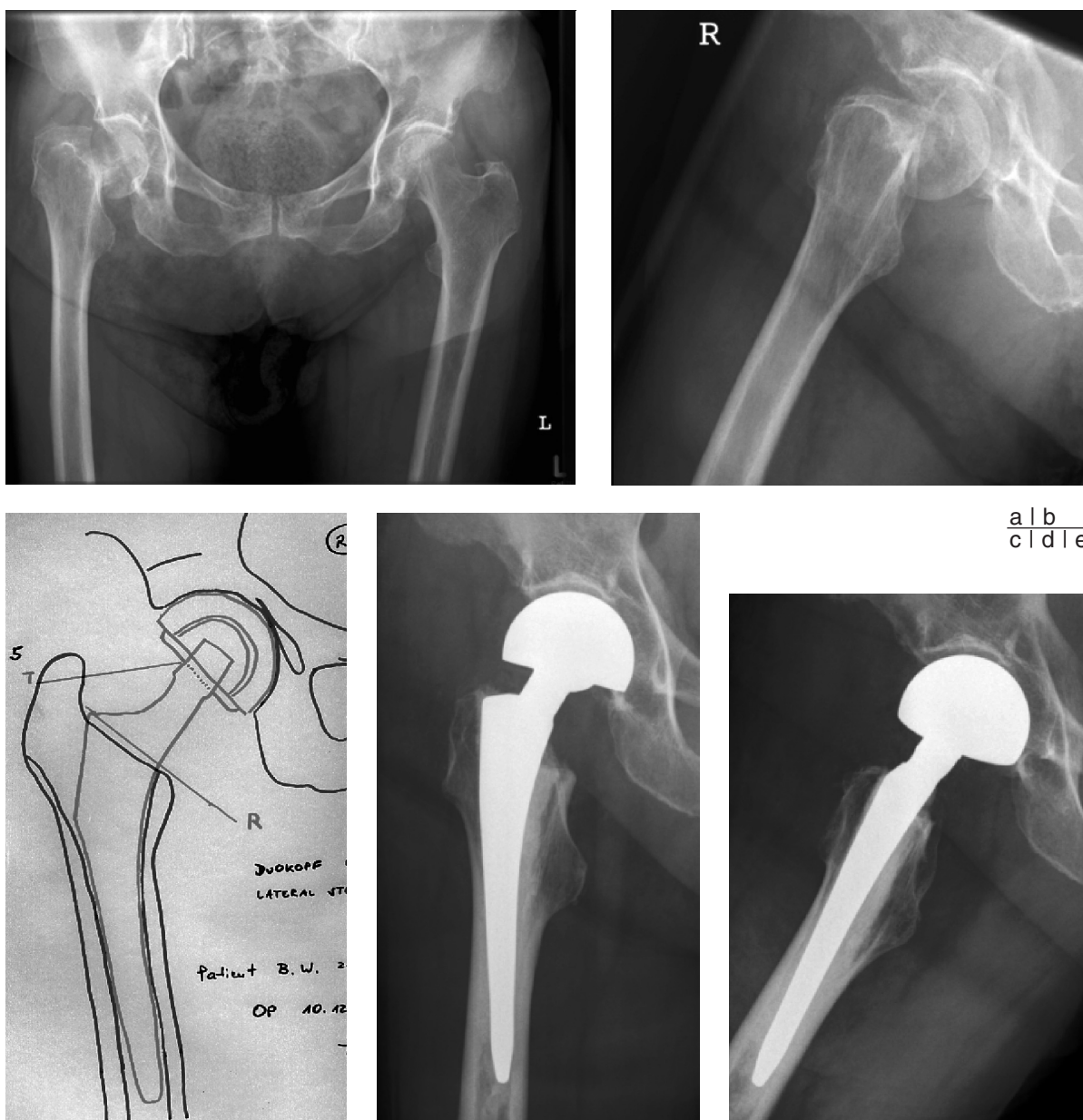

Image 11a–e. Eighty-five-year-old female patient after breaking the flat open. The overview of the pelvis and the Lauenstein-photo show the dislocated Garden IV fracture (a, b); decision to implant a hemiendoprosthesis: preoperative planning scheme (c); postoperative x-ray-image of the implanted cemented bipolar prosthesis (d, e).

the capsule can minimize the risk for luxation. Therefore the Kocher-Langenbeck approach can equal the other standard approaches (35). Essentially the modern minimally invasive approaches are also suitable for endoprosthetic provision of the hip joint after fracture of the femoral neck. Long time results still are yet to come. Physiologic position of the acetabulum with 15–25° of antetorsion and 45° of inclination should be aimed for. Also the fitting, a stable fixation of the stem and imitation of the physiological axes have to be precise. The adjustment of the acetabular cup component imitates the anatomic tilt of the acetabulum. Proper positioning of the stem component is achieved by careful and muscle sparing preparation of the outward rotated and adducted shaft of femur by bone raspatory. In order

to avoid embolisms from the bone marrow cavity, careful preparation and usage of the jet-lavage in the cavity right before the cementation is recommended. The correct measurements of the head are being taken from the extracted head of femur via gauge. The optimal adjustment of the soft tissue can be controlled by using variable and modular lengths of the head component and reposition with a probational prosthesis. Regarding the question of either a cemented or an uncemented hip replacement the bone quality somewhat determines its use. For the older patient with osteoporosis it is recommended, since it allows a neat form fit of the prosthesis component to the bone. Furthermore it allows immediate full weight bearing. According to the literature the results of treating fractures of the femoral neck by endo-

prosthesis using cement are equal to those implanted cementfree (18). Eventually the younger and more active patient should rather be provided with a cementless prosthesis other than the frail, geriatric patient.

Complication management

The risk for intraoperative, periprosthetic fracture is higher with cementless, press fitted endoprosthesis (up to 3–5%). They should be identified intraoperatively and be treated according to the principles of the therapy of periprosthetic fractures. Shaft perforations, cement leakage into the soft tissue and unsatisfying positioning of the implant like varus positions, shortening or lengthening of the affected leg as well as non-anatomic anteversion of the femur can be detected intraoperatively and corrected using a x-ray imager. If not recognized intraoperatively, these conditions will entail the risk of luxation of the hip replacement. Despite the use of modern orthoses intractable luxations can only be solved by replacement of the prosthesis.

The complication feared most with endoprostheses for the treatment of the fracture of the femoral neck is the early infection. An early decompression of the hematoma and repeated irrigation of the joint with debridement of the infected soft tissue as well as a systemic antibiotic therapy subject to the tested resistance can preserve the synthetic joint in rare cases. Depending on the course of the clinic, the parameters indicating systemic infection (C-reactive protein, CRP) and the robustness of the patient two to five attempts to control the infection surgically can be reasonable. If these efforts prove ineffective the complete removal of all implanted material including all components and the cement is inevitable.

Only if the patient is verifiably free of infection (CRP <5) the reimplantation of a prosthesis is reasonable. This should take place 3 months after the removal of all components at the earliest.

The spectrum of germs in late infection is entirely different to that of the early infection. Late infection induces loosening of the implant. The diagnosis can be verified by exploratory puncture of the hip joint and laboratory parameters in combination with imaging. In these cases the replacement of the implant in one or two steps using cement containing antibiotics is the treatment of choice. This should be done once microbial detection and antibiotic sensitivity testing is available. Differences in leg length > 1.0 cm can be corrected via adjustment of shoe support.

References

1. BACHILLER, F. G., CABALLER, A. P., PORTAL, L. F.: Avascular necrosis of the femoral head after femoral neck fracture. *Clin. Orthop.* 87–109, 2002.
2. BAKER, R. P., SQUIRES, B., GARGAN, M. F., BANNISTER, G. C.: Total hip arthroplasty and hemiarthroplasty in mobile, independent patients with a displaced intracapsular fracture of the femoral neck. A randomized, controlled trial. *J. Bone Jt Surg.*, 88-A: 2583–2589, 2006.
3. BARNES, R., BROWN, J. T., GARDEN, R. S., NICOLL, E. A.: Subcapital fractures of the femur. A prospective review. *J. Bone Jt Surg.* 58-B: 2–24, 1976.
4. BARTOSKA, R.: Measurement of femoral head diameter: a clinical study. *Acta Chir. orthop. Traum. čech.*, 76: 133–136, 2009.
5. BLOMFELDT, R., TORNKVIST, H., PONZER, S., SODERQVIST, A., TIDERMARK, J.: Displaced femoral neck fracture: comparison of primary total hip replacement with secondary replacement after failed internal fixation: a 2-year follow-up of 84 patients. *Acta Orthop.*, 77: 638–643, 2006.
6. BONNAIRE, F.: Neue Aspekte zur Biomechanik und Osteosynthese von Schenkelhalsfrakturen. *Hefte zur Zeitschrift Der Unfallchirurg*, 2000.
7. BONNAIRE, F., KUNER, E. H., LORZ, W.: Femoral neck fractures in adults: joint sparing operations. II. The significance of surgical timing and implant for development of aseptic femur head necrosis. *Unfallchirurg*, 98: 259–264, 1995.
8. BONNAIRE, F., MULLER, B., KOHLBERGER, E.: Kopferhaltende Operationsmethoden bei der Schenkelhalsfraktur des Erwachsenen. *Hefte Unfallchir.*, 228: 44–75, 1993.
9. BONNAIRE, F. A., WEBER, A. T.: The influence of haemarthrosis on the development of femoral head necrosis following intracapsular femoral neck fractures. *Injury*, 33 Suppl 3: C33–40, 2002.
10. CALDER, S. J., ANDERSON, G. H., JAGGER, C., HARPER, W. M., GREGG, P. J.: Unipolar or bipolar prosthesis for displaced intracapsular hip fracture in octogenarians: a randomised prospective study. *J. Bone Jt Surg.*, 78-B: 391–394, 1996.
11. CHENG, J. C., TANG, N.: Decompression and stable internal fixation of femoral neck fractures in children can affect the outcome. *J. Pediatr. Orthop.*, 19: 338–343, 1999.
12. CHO, M. R., LEE, S. W., SHIN, D. K., KIM, S. K., KIM, S. Y., KO, S. B., KWUN, K. W.: A predictive method for subsequent avascular necrosis of the femoral head (AVNFH) by observation of bleeding from the cannulated screw used for fixation of intracapsular femoral neck fractures. *J. Orthop. Trauma*, 21: 158–164, 2007.
13. CORNELL, C. N., LEVINE, D., O'DOHERTY, J., LYDEN, J.: Unipolar versus bipolar hemiarthroplasty for the treatment of femoral neck fractures in the elderly. *Clin. Orthop.*, 67–71, 2007.
14. CRAWFURD, E. J., EMERY, R. J., HANSELL, D. M., PHELAN, M., ANDREWS, B. G.: Capsular distension and intracapsular pressure in subcapital fractures of the femur. *J. Bone Jt Surg.*, 70-B: 195–198, 1988.
15. DAVIS, F. M., WOOLNER, D. F., FRAMPTON, C., WILKINSON, A., GRANT, A., HARRISON, R. T., ROBERTS, M. T., THADAKA, R.: Prospective, multi-centre trial of mortality following general or spinal anaesthesia for hip fracture surgery in the elderly. *Brit. J. Anaesth.*, 59: 1080–1088, 1987.
16. EIJER, H., MYERS, S. R., GANZ, R.: Anterior femoroacetabular impingement after femoral neck fractures. *J. Orthop. Trauma*, 15: 475–481, 2001.
17. ENDRES, H. G., DASCH, B., LUNGENHAUSEN, M., MAIER, C., SMEKTALA, R., TRAMPISCH, H. J., PIENKA, L.: Patients with femoral or distal forearm fracture in Germany: a prospective observational study on health care situation and outcome. *BMC Public Health*, 6: 87, 2006.
18. FIGVED, W., OPLAND, V., FRIHAGEN, F., JERVIDALO, T., MADSEN, J. E., NORDSLETTEN, L.: Cemented versus uncemented hemiarthroplasty for displaced femoral neck fractures. *Clin. Orthop.*, 467: 2426–2435, 2009.
19. GARDEN, R. S.: Malreduction and avascular necrosis in subcapital fractures of the femur. *J. Bone Jt Surg.* 53-B: 183–197, 1971.

20. GILLESPIE, W. J., WALENKAMP, G.: Antibiotic prophylaxis for surgery for proximal femoral and other closed long bone fractures. *Cochrane Database Syst Rev*: CD000244, 2001.
21. GURUSAMY, K., PARKER, M. J., ROWLANDS, T. K.: The complications of displaced intracapsular fractures of the hip: the effect of screw positioning and angulation on fracture healing. *J. Bone Jt Surg.*, 87-B: 632–634, 2005.
22. ITADERA, E., ICHIKAWA, N., YAMANAKA, N., OHMORI, T., HASHIZUME, H.: Femoral neck fractures in older patients: indication for osteosynthesis. *J. Orthop. Sci.*, 8: 155–159, 2003.
23. JAIN, R., KOO, M., KREDER, H. J., SCHEMITSCH, E. H., DAVEY, J. R., MAHOMED, N. N.: Comparison of early and delayed fixation of subcapital hip fractures in patients sixty years of age or less. *J. Bone Jt Surg.*, 84-A: 1605–1612, 2002.
24. KOPP, L., EDELMANN, K., OBRUBA, P., PROCHAZKA, B., BLSTAKOVA, K., DZUPA, V.: Mortality risk factors in the elderly with proximal femoral fracture treated surgically. *Acta Chir. orthop. Traum. čech.*, 76: 41–46, 2009.
25. KOUDELA, K., KASAL, E., MATEJKA, J., VYSKOCIL, V.: Geriatric traumatology – vision or reality? *Acta Chir. orthop. Traum. čech.*, 76: 338–343, 2009.
26. KRISCHAK, G., BECK, A., WACHTER, N., JAKOB, R., KINZL, L., SUGER, G.: Relevance of primary reduction for the clinical outcome of femoral neck fractures treated with cancellous screws. *Arch. Orthop. Trauma Surg.*, 123: 404–409, 2003.
27. LOKEN, S., ANDREASSEN, G. S.: Surgery of femoral neck fractures-higher rate of osteosynthesis with the use of 4,5 mm screws compared to 6,5 mm screws. *T. norske Loegeforen*, 121: 2474–2475, 2001.
28. LUTONSKY, M., VALIS, M., SROT, J.: Total hip arthroplasty after femoral neck fracture in patients with acquired neurological deficit. *Acta Chir. orthop. Traum. čech.*, 76: 239–242, 2009.
29. MAJERNICEK, M., DUNGL, P., KOLMAN, J., MALKUS, T., VACULIK, J.: Osteosynthesis of intracapsular femoral neck fractures by dynamic hip screw (DHS) fixation. *Acta Chir. orthop. Traum. čech.*, 76: 319–325, 2009.
30. MALCHAU, H., WANG, Y. X., KARRHOLM, J., HERBERTS, P.: Scandinavian multicenter porous coated anatomic total hip arthroplasty study. Clinical and radiographic results with 7- to 10-year follow-up evaluation. *J. Arthroplasty*, 12: 133–148, 1997.
31. MANNINGER, J., KAZAR, G., FEKETE, G., NAGY, E., ZOLCZER, L., FRENYO, S.: Avoidance of avascular necrosis of the femoral head, following fractures of the femoral neck, by early reduction and internal fixation. *Injury*, 16: 437–448, 1985.
32. MÜLLER, M. E.: Fractures of the femoral head. In: Müller, M. E., Allgöwer, M., Schneider, R., Willenegger, H. (eds): *Manual of internal fixation: techniques recommended by the AO-ASIF group*, 1991, 519–521.
33. NILSSON, L. T., JALOVAARA, P., FRANZEN, H., NIINIMAKI, T., STROMQVIST, B.: Function after primary hemiarthroplasty and secondary total hip arthroplasty in femoral neck fracture. *J. Arthroplasty*, 9: 369–374, 1994.
34. PAPANDREA, R. F., FROIMSON, M. I.: Total hip arthroplasty after acute displaced femoral neck fractures. *Amer. J. Orthop.*, (Belle Mead NJ) 25: 85–88, 1999.
35. PARKER, M. J., RAGHAVAN, R., GURUSAMY, K.: Incidence of fracture-healing complications after femoral neck fractures. *Clin. Orthop.*, 458: 175–179, 2007.
36. PEREZ, J. V., WARWICK, D. J., CASE, C. P., BANNISTER, G. C.: Death after proximal femoral fracture-an autopsy study. *Injury*, 26: 237–240, 1995.
37. SCHLEICHER, I., KORDELLE, J., JURGENSEN, I., HAAS, H., MELZER, C.: Femoral neck fractures in the elderly – bipolar hemiarthroplasty in total hip replacement. *Unfallchirurg*, 106: 467–471, 2003.
38. SQUIRES, B., BANNISTER, G.: Displaced intracapsular neck of femur fractures in mobile independent patients: total hip replacement or hemiarthroplasty? *Injury*, 30: 345–348, 1999.
39. STÜRMER, K. M.: *Leitlinien der Unfallchirurgie* (4. Ausgabe). 2008.
40. WU, C. C., CHEN, W. J.: Minimally displaced intra-capsular femoral neck fractures in the elderly-comparison of multiple threaded pins and sliding compression screws surgical techniques. *J. Orthop., Surg. (Hong Kong)*, 11: 129–136, 2003.

Corresponding author:

Dr. med. Thomas Lein

Department for Trauma-, Reconstructive and Hand surgery,

Hospital Dresden-Friedrichstadt, Academic Teaching

Hospital of the Technical University of Dresden

Friedrichstrasse 41

D-01067 Dresden, Germany

E-mail: lein-th@khdf.de