

# Open Fractures and Infection

## Otevřené zlomeniny a infekce

Th. NEUBAUER<sup>1</sup>, G. S. BAYER<sup>2</sup>, M. WAGNER<sup>1</sup>

<sup>1</sup> Department of Traumatology, Wilhelminenspital der Stadt Wien, Austria

<sup>2</sup> Department of Plastic and Reconstructive Surgery, Wilhelminenspital der Stadt Wien, Austria

### SUMMARY

Open fractures still represent a major challenge for the treating surgeon and frequently demand a complex of soft tissue and bone procedures to achieve an undisturbed healing with adequate limb function. However, despite improvement in operative techniques and antibiotic therapy septic complications still occur in severe open fracture forms up to 50%. They are still deleterious for the patient as well as a major economic factor for the treating hospital. Radical (repetitive) debridement of the wound and coverage of soft tissue defects are of utmost importance in the prophylaxis of septic complications along with antibiotic therapy. If the local wound requires flap coverage, early performed procedures yield a clear decrease of infection rates even in most severe fracture forms. Osseous stabilization contributes to infection prophylaxis, especially when the implants can be inserted in a minimal invasive way and provide an adequate handling of soft tissues and the wound. Thus, most often intramedullary nails and external fixators are used today for osteosynthesis. Recently developed plates with angular stability offer a promising alternative even in open fractures, especially when there is an extension of the fracture into the metaphyseal area though indications have to be evaluated. Manifest septic complications demand an early and aggressive approach with radical eradication of the septic topic. While acute infections require most often only minor surgical procedures and offer the chance to leave implants in situ, chronic infections usually demand complex reconstructive measures of bones and soft tissues.

**Key words:** open fractures, classification, soft tissue coverage, infection.

### INTRODUCTION

Infection still represents one of the major complications in the treatment of open fractures though results have improved during the last century. Break down of the tissue barrier between the fracture zone and the environment leaves the underlying bone prone to direct contact with contaminating agents, mirrored in positive wound cultures up to 60 %–70 % (22, 57, 58). Figures from the 19<sup>th</sup> century demonstrate that in preceding centuries the major concern was the survival of the patient with primary mortality rates of about 50 % and another 40 % mortality in subsequent amputations (24, 42). Due to improved aseptic and operative techniques, survival rates of the patients increased. However, loss of the injured extremity due to wound infection and non-union was of major concern, especially when combined with a major vascular trauma (9). Though survival of the patient as well as salvage of the extremity can be achieved today in most patients, open fractures are still prone to complications. *Ochsner* (49) found in ORIF procedures an over-all infection rate of 6,2 % in open fractures compared to 1,9 % in closed fractures. Depending on the anatomic site and on the severity of soft-tissue trauma up to 50 % infectious complications have been reported (15, 22, 73) with the tibia being most often affected (53, 64). Thus, subsequent chronic osteitis and/or non-union still represent today a major source of disability and decreased quality of life for the

individual patient as well as a socio-economic problem for public health systems.

### CLASSIFICATION

As the severity and amount of the soft tissue damage determine a complex treatment concept of surgical and conservative measures, classification of these fractures is of utmost importance. The classification system of *Gustilo et al.* was established in 1976 (22) and still included important parameters like the skin wound, amount of muscle damage and fracture type (Table 1), which allowed to draw therapeutic conclusions for an individual fracture. *Gustilo et al.* (23) modified the classification in 1984 by dividing fracture type III into subclasses A, B and C (Table 2) depending on the coverage of bone by soft tissues and vascular compromise, respectively. Though accused of high inter-observer errors due to subjective influence on injury description (4), *Gustilo's* system still represents a global classification system for open fractures. Its simplicity makes it prone for the use in clinical routine and its subgroups allow prognostic conclusions in respect to possible complications, which increase with *Gustilo's* classification number (43, 45, 73). *Muhr* (47) reported in a survey of the literature the risk of acute infection in open fractures *Gustilo's* grade I with 0 %–2 %, in type II fractures of 5 % and in type III fractures of up to 10 %–25 %, respectively. *Weiz-Marschall* (73) found a similar distribution

Table 1. Classification of open fractures according to Gustilo (22)

---

Type I: laceration < 1 cm, clean
Type II: laceration > 1 cm, without extensive soft tissue damage, flaps or avulsions
Type III: open segmental fracture or extensive soft tissue damage or traumatic amputation

---

Table 2. Sub-classification of most severe open fracture forms (G III) according to Gustillo (23)

---

Type IIIA: severe soft tissue damage, but bones are still covered by vital muscles or periosteum
Type IIIB: bone exposed, not covered by vital muscles or periosteum
Type IIIC: all open fractures with arterial damage, which require vascular repair for limb salvage

---

Table 3. Classification of open fractures according Tscherne and Oestern (68)

---

Fr. O I: Perforation of skin without or with minimal contusion and insignificant contamination. Skin perforated by fracture fragment.
Fr. O II: Perforation of skin with circumscribed contusion and medium contamination, all fracture forms.
Fr. O III: Perforation of skin with distinct soft tissue damage and frequent vascular and neural compromise. Gunshot fractures and rural fractures with severe contamination are summarized in this group as well as all open fractures with a major vascular injury.
Fr. O IV: Total or subtotal amputation (dissection of all important anatomic structures, especially major vessels; remaining soft tissue envelope maximal one quarter of circumference).

---

Table 4. Classification of open fractures according to the Arbeitsgemeinschaft für Osteosynthesefragen (AO) (63)

#### Skin lesion (IO):

---

IO 1: skin lesion from inside out
IO 2: skin lesion from outside and less than 5 cm, moderate contusion of wound edges
IO 3: skin lesion from outside and greater than 5 cm, contusion and devitalized edges
IO 4: contusion of all layers, abrasion, extensive degloving injury, skin loss

#### Muscle / tendon lesions (MT):

---

MT 1: no muscle injury
MT 2: one muscle compartment, circumscribed injury
MT 3: two muscle compartments, considerable injury
MT 4: muscle defect, tendon laceration, extensive contusion
MT 5: compartment syndrome / crush syndrome

#### Neurovascular lesions (NV):

---

NV 1: no neurovascular injury
NV 2: isolated neural lesion
NV 3: localized vascular lesion
NV 4: segmental vascular damage
NV 5: combined neurovascular injury (inc. sub-/total amputation)

---

in the American literature with 0 % infection rate in type I, up to 12 % in type II and up to 50 % in type III fractures.

Other classification systems like the classification system of *Tscherne and Oestern* (68) (Table 3) and the *AO Müller Classification* (63) (Table 4) provide more refined descriptions of the local situation, as lesions of bone, soft tissues and neurovascular structures and the grade of contamination are evaluated separately. On the other hand their detailed classification of different parameters in an open fracture result in a descriptive complexity, which makes communication in daily routine more difficult than Gustillo's classification. In many fractures the whole amount of soft tissue damage can be comprehended yet a few days after the trauma, when demarcation of necroses is delayed (Fig. 1). Thus, independently on the system used, classification of an open fracture should be re-evaluated after the initial debridement (68).

## PATHOMECHANISM OF INFECTION

### Contamination and virulence

Contamination of the wound is dependent on the kind of accident with rates of primary colonization being reported as high as 70 %–80 % (23, 37, 58, 59). Smears reveal most often Gram-positive *Staph. aureus* and epidermidis and in Gram-negative species *Bacilli*, *Pseudomonas*, *Acinetobacter* or *Enterobacteriaceae* (22, 40, 45, 51, 52, 61, 64). Though the microbiological pattern at the wound site may be influenced by environmental factors (agricultural injury, gun-shot injury, water injury...) which have to be considered in the antibiotic management (37, 66, 76) it is well known that most infections in open fractures are of nosocomial origin as causative micro-organisms of infection are different to those found in initial smears (40, 45). *Kindsfater et al.* (37) reported that 25 % of infections were caused by micro-organisms found in initial examinations and *Lee* (40) evaluated only 8 % of microorganisms on pre-debridement cultures to be the infectious agents. Thus, infection rates can be positively influenced by prophylactic, hygienic requirements. *Rojczyk et al.* (58) demonstrated that coverage of the wound with a sterile dressing at the accident site and its removal under sterile conditions in the operating room can reduce the infection rate from 19,2 % to 4,3 % (Fig. 2).

In contrast to their number the virulence of inoculated micro-organisms cannot be influenced in the stadium of the acute trauma. Only a long lasting and global change of treatment strategies with avoidance of uncritical and unexperienced use of antibiotics can provide a successful reduction of the selection and infection with problematic micro-organisms like multiresistant staphylococci (MRSA / MRSE, ORSA / ORSE).

### Local and general factors of defence

Vascularity at the fracture site represents the most important factor in the local defence of inoculated micro-organisms. Its importance is mirrored in high

rates of infectious complications (11, 64, 66) in Gustilo's IIC fractures. Additionally, wound morphology at the fracture site contributes to the multiplication of microorganisms when caves, restricted fluids or hematomas provide an excellent local environment. From a biological point of view fracture stabilization with implants increases the local compromise to the soft tissues by adding a surgical trauma and inserting a foreign body (45). On the other hand, there is evidence that fracture stabilization decreases the rate of septic complications (25, 74). Thus, osteosynthesis techniques preserving the soft tissues by a minimal approach while providing a high amount of stability will contribute to the prophylaxis of infection. For diaphyseal fractures these techniques include the external fixator, the unreamed nail and minimal invasively inserted plates bridging the fracture zone.

### Systemic factors

As most open fractures are caused by considerable trauma, the percentage of associated injuries in these patients is high and polytrauma not uncommon. Muhr (48) reported in a survey of the literature 30 % polytrauma patients among open fractures and Schandelmeier *et al.* (60) found in a group of IIIB tibia fractures only 18 % isolated injuries. Therefore additional systemic compromise due to multiorgan failure or a suppressed immune system may influence the local situation in these patients. In elderly patients and low-energy trauma pre-existing vascular disease may add further compromise to the local situation, especially in certain anatomic areas – like the tibia – with preexisting critical vascularity.

### THERAPY OPTIONS

Open fractures are emergencies and require prompt and adequate treatment including a complex of combined bone and soft tissue procedures. The aim of treatment in open fractures is the restoration of the limb's full function by an adequate healing of soft tissues and bone without infection (26, 66). By respecting the established therapeutic principles complications, especially infection rates, can be improved dramatically (Table 5).

#### Local debridement and soft-tissue care

The quality of the initial debridement represents the key-point in the treatment of open fractures and their infection prophylaxis (66). Radical removal of all devitalized tissues along with a copious irrigation of the wound are of paramount importance (22, 35, 48) as the nutritive basis for micro-organisms is removed and the number of inoculi can be reduced by 80 % (47). However, one has to consider that irrigation with high pressure pulsatile systems can add tissue damage and propagate foreign bodies or bacteria deeper into the wound (27). Debridement must include all bone areas of uncertain vascularity, which can decrease infection rates dramatically by 33 % (12).

The time elapsing between injury and the start of operative wound debridement is considered as an important

factor contributing to the prophylaxis of wound infections (11, 26, 31, 36, 37). Though not proofed by evidenced data, a positive influence on bone healing and wound infections can be observed when initial debridement is started within 6 hours from injury.

In most severe soft tissue damage even primary amputation has to be considered, to avoid prolonged disability and a limb without function after many reconstruction attempts. Especially in polytrauma patients with a critical general state the rule "limb for life" still has its values. Objective and absolute criterias for primary amputation in open tibia fractures were defined by Lange *et al.* (39) as a prolonged ischemia of more than 6 hours in IIC fractures and a complete destruction of the posterior tibial nerve with loss of protective sensation in adults. Discrimination between a salvagable or non-salvagable extremities may be supported by the MESS-score (28). It represents a relative easily assessable scoring system, where values of >7 pts. being absolute predictable for amputation (Table 6).

Table 5. Decrease of infection rates in open tibia fractures by radical local debridement

Author	Year	Infection rate (%)	
		no radical debridement, no primary open wound management	radical debridement and primary open wound management
Gustilo (22)	1976	44 %	9 %
Patzakis (53)	1983	14 %	4,5 %
Russel (59)	1990	20 %	3 %
Ketterl (35)	1990	30 %	12 %
Muhr (48)	1991	17 %	2,5 %

Table 6. Mangled extremity score (28)

#### Skeletal / soft tissue:

- low energy: stab wounds, simple closed fractures, small caliber gunshot 1
- medium energy: open or multi-level fractures, dislocations, moderate crush-injuries 2
- high energy: shotgun blast, high velocity gunshot wounds 3
- massive crush: railroad, oil rig accidents etc. 4

#### Shock:

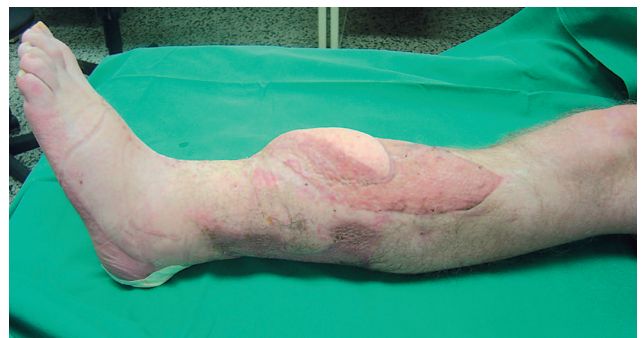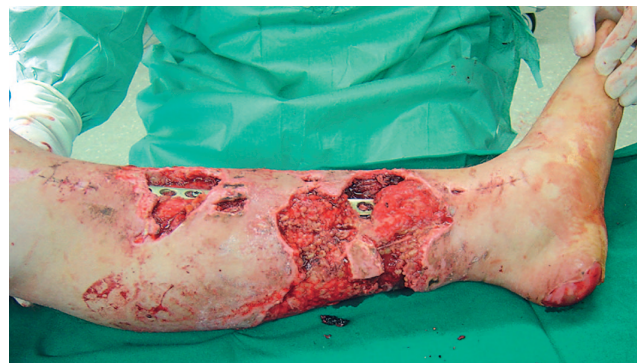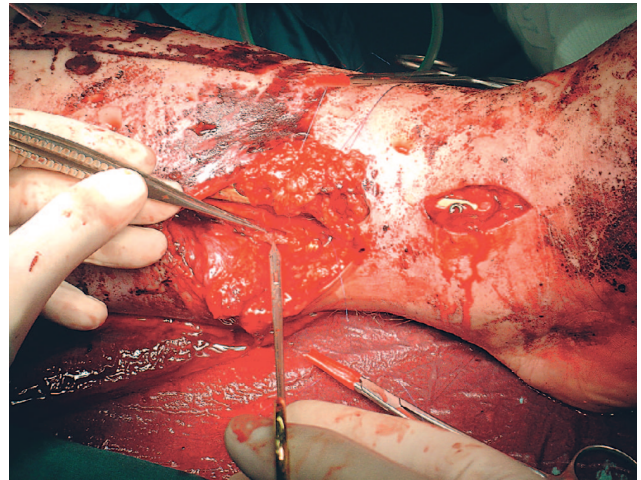
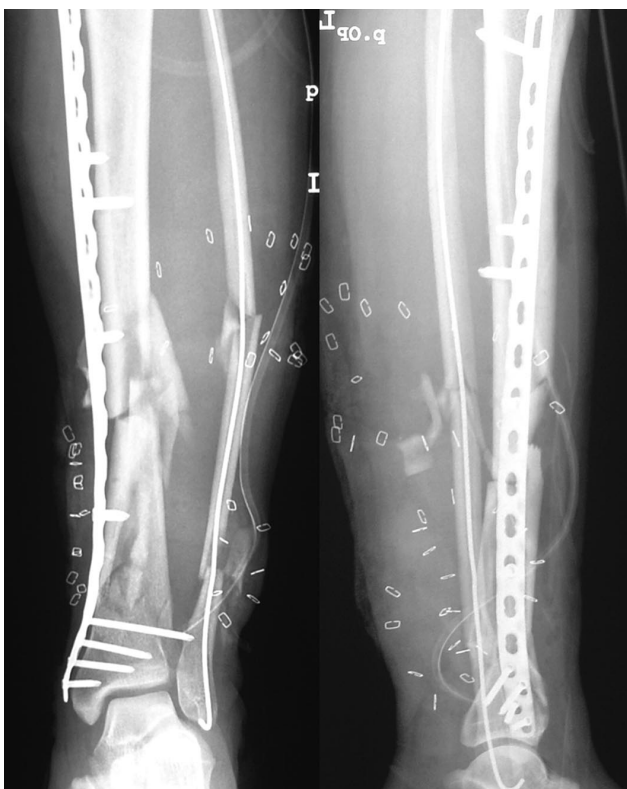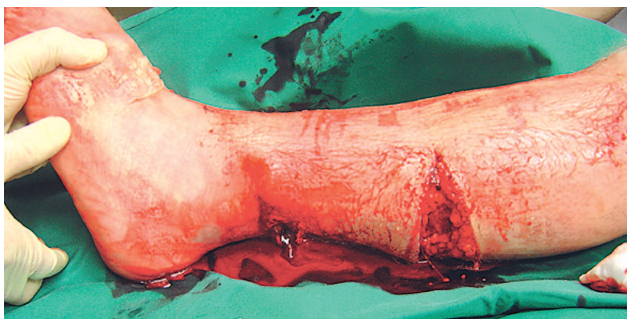
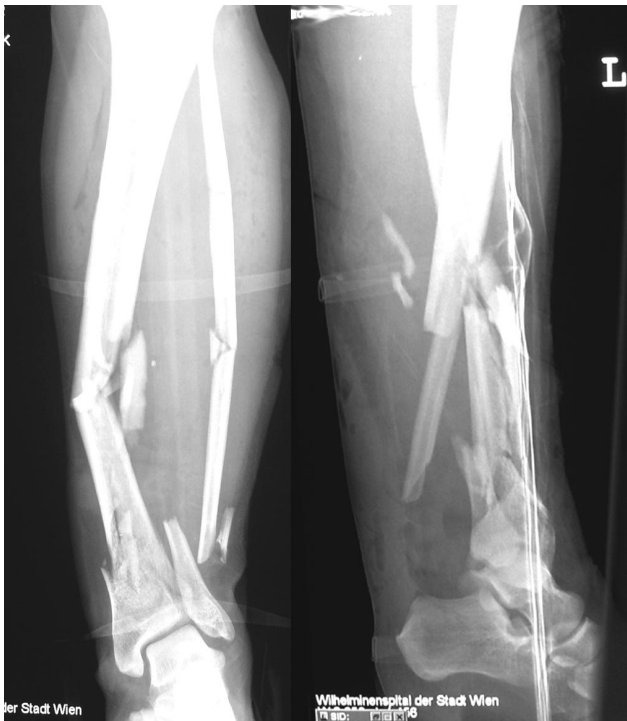- normotensive 0
- transient hypotensive, responsive to i. v. fluids 1
- prolonged hypotension, systolic RR < 90, responsive only in OR 2

#### Ischemia (points doubled, if exceeding six hours):

- none 0
- mild, diminished pulses without ischemia 1
- moderate, no pulse by Doppler, sluggish capillary refill, paresthesia, diminished motor activity 2
- pulseless, cool, paralyzed and numb without capillary refill 3

#### Age:

- < 30 years 0
- > 30 < 50 years 1
- > 50 years 2

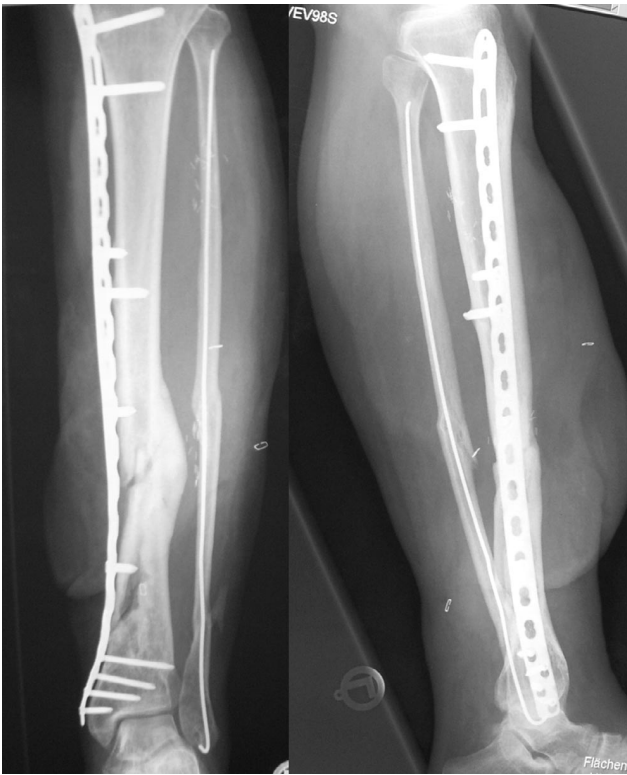

a	d
b	e
c	f

→

Fig. 1. Z. W., 39 years, motorcycle accident, male, sustained open tibial fracture Gustillo IIIc, with traumatic dissection of the posterior tibial artery:

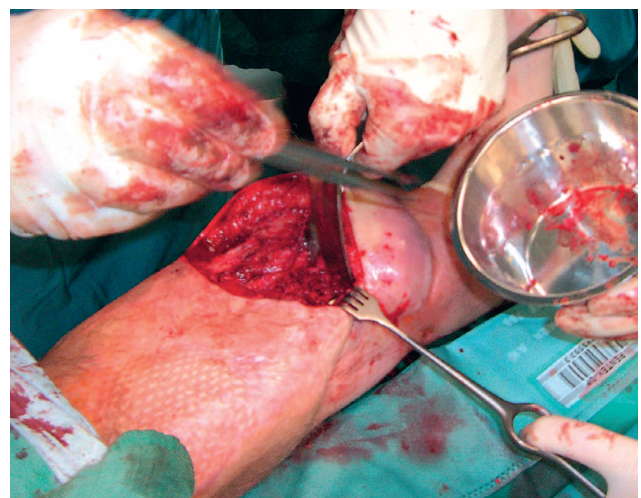
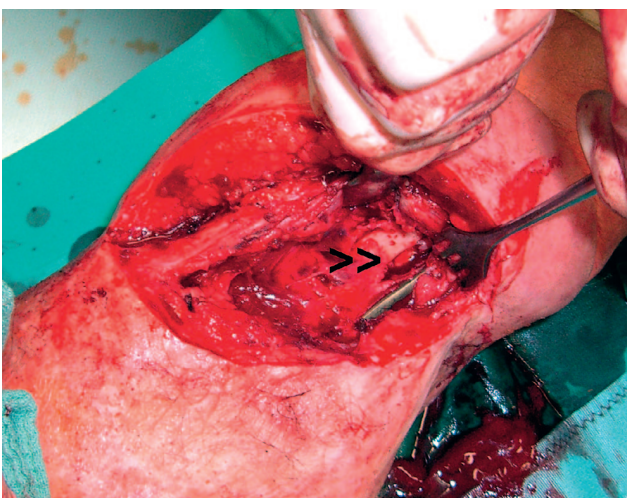
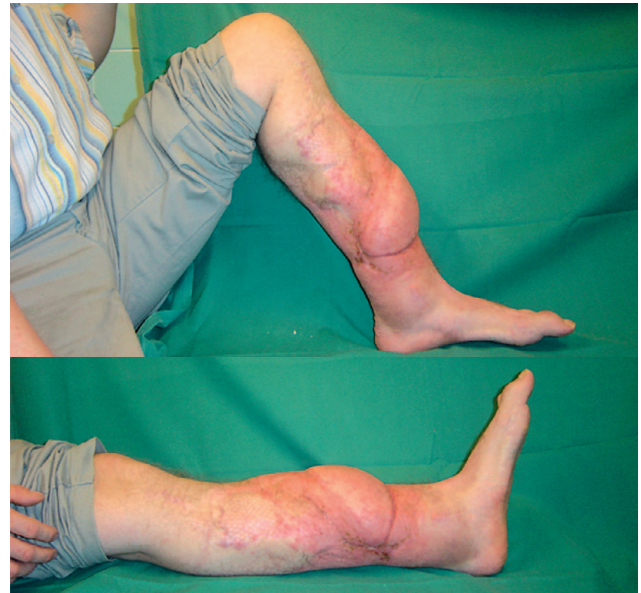
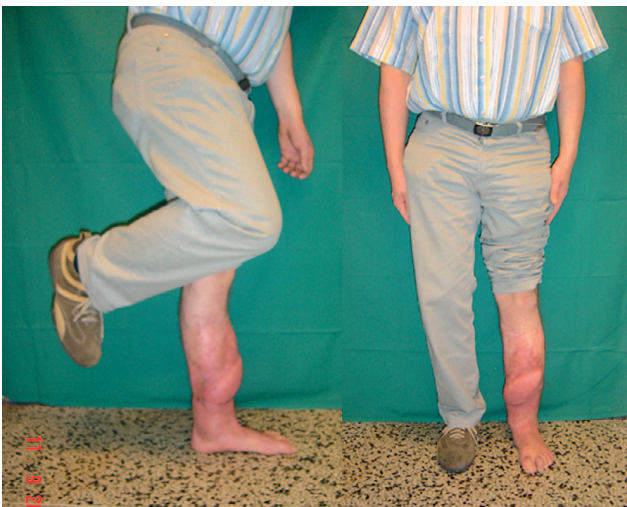- Osseous lesion represented an irregular 43-C.3 fracture with an associated segmental fibula fracture at three levels.
- Dorsomedial laceration of the skin with distinct subcutaneous degloving injury, local muscle destruction and disruption of the posterior tibial artery; (AO – class.: 43 C3, IO4, MT4, NV3).
- After emergency debridement and surgery of the soft tissues the resulting skin defects were left open and covered temporarily with Epigard®. The tibia was fixed with a LCP-distal tibia plate inserted via minimal invasive approach while the segmental fibula fracture was stabilised with ESIN rod.
- End – end anastomosis of the posterior tibial artery at emergency surgery.

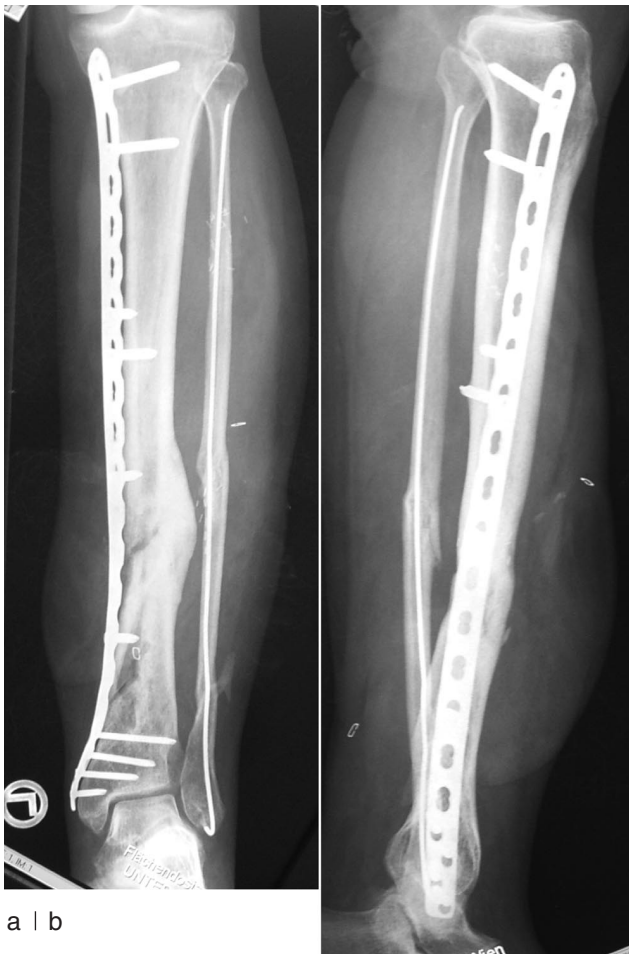

g	
h(a)	h(b)
i(a)	i(b)

- e) Follow-up debridements resulted in distinct skin and soft tissue defects dorsomedially, though arterial repair was still covered by vital tissues.
- f) Proximal defect was covered by a gastrocnemius flap and healed uneventful. Distal defect was covered by a free vascularized gracilis flap, which was lost due to venous thrombosis. Revision surgery after flap removal and coverage with microvascular latissimus dorsi flap showed successful healing without infection. Soft tissue situation 6 months after coverage.
- g) Radiographs 18 months after trauma reveal osseous bridging of the fracture zone on the lateral side, though medial bridging is uncertain.
- h) 18 months after trauma patient works in preinjury occupation and shows unlimited range in knee and ankle joint, though some pains are reported in the lower leg after long distance walking (a, b).
- i) 24 months after initial treatment local debridement at the medial cortex beneath the plate (>>) and cancellous bone grafting was performed (a, b).

→





j) 8 weeks after bone grafting the patient had an unlimited ability of walking without any pains and radiographs revealed beginning bony bridging beneath the plate (a, b).

### Antibiotic treatment

Systemic administration of antibiotics represented one key-point in Gustilo's treatment concept (22) and it has been proved that the infection rate in open fractures can be reduced by it. *Patzakis et al.* (51) demonstrated in a prospective, randomized trial of 333 open fractures that infection rates decreased to 2,3 % by the administration of cephalothin compared to 13,9 % infections in the group without antibiotic treatment. The selection of antibiotics should be based on the microbiological findings and must especially cover nosocomial pathogens like *Staphylococcus aureus*, Gram negative bacilli or *Pseudomonas aeruginosa* (22, 51, 57, 66, 74). A widely used combination, covering Gram positive as well as Gram negative microorganisms, includes a first generation cephalosporine and aminoglycosides (45, 76); it can be adapted to special injury patterns and environmental situations like farmyard accidents, water injury or wounds with fecal contamination (66). Antibiotic treatment should be started as soon as possible after the injury and maintained long enough to destroy all microorganisms. On the other hand development of resistant pathogens and secondary infections under a prolonged

therapy have to be avoided. Therefore, it seems reasonable to limit antibiotic treatment for three days with repeated three days administrations for major surgical procedures and for wound closure (52, 66, 76).

### Local antibiotic carriers

Local antibiotic carriers provide high tissue levels of the drugs and almost no systemic toxicity, which is especially useful in severe soft-tissue damage and gross contamination and/or impaired vascularity. Most often gentamycin augmented beads are used to support the antimicrobial activity of parenteral administered antibiotics (46, 50). *Ostermann et al.* (50) observed a decrease of the overall infection rate of open fractures from 12 % down to 3,7 % when an antibiotic therapy with tobramycin, cefazolin and penicillin was supplemented by local antibiotic beads. This difference seems to be especially significant in severe fracture forms (62). Antibiotic beads can fill contaminated primary or secondary bone defects till they can be definitively operated on.

### Fracture stabilization

Most open fractures – especially of higher grade (GII/GIII) – are unstable and require surgical fixation. Apart from facilitated nursing and early mobilization of the patient the mechanic stability achieved by osteosynthesis contributes to the prophylaxis of bone / soft-tissue infections (74). The choice of implant must be adapted to the "personality of the fracture", especially the anatomic site, the amount of soft tissue damage and the degree of contamination. Implant selection in the acute situation sometimes has to find a compromise between an optimal biomechanic solution and a possible implant-interference with local wound management. So external fixators, intramedullary nails (IMN) and percutaneously inserted plates are viable options in open fractures. However, definitive stabilization must not be achieved initially at all costs as temporary administration of an external fixator with conversion to internal fixation after soft tissues recovery represents a reasonable treatment concept (2).

### External fixator (E. F.)

Application of an E. F. is usually quickly achieved with no implant material submerged beneath the skin. Thus, heavily contaminated fractures, extensive soft tissue damage or selected situations of polytraumatized patients are prone to the treatment with external fixators as the fixator pins usually do not interfere with local wound care. However, the pin positions have to be considered when a flap coverage is planned, to avoid irritation of the flap design. Furthermore, external fixation alone till osseous union is affected by complications at the pin sites, malunion, refractures, deep infection and non-union. Septic complications often originate from pintrack infections (12, 21, 29) when conversion to intramedullary stabilization is delayed (15) where infection rates of nearly 50 % are reported (44). On the other hand *Blachut et al.* (2) yielded excellent functional

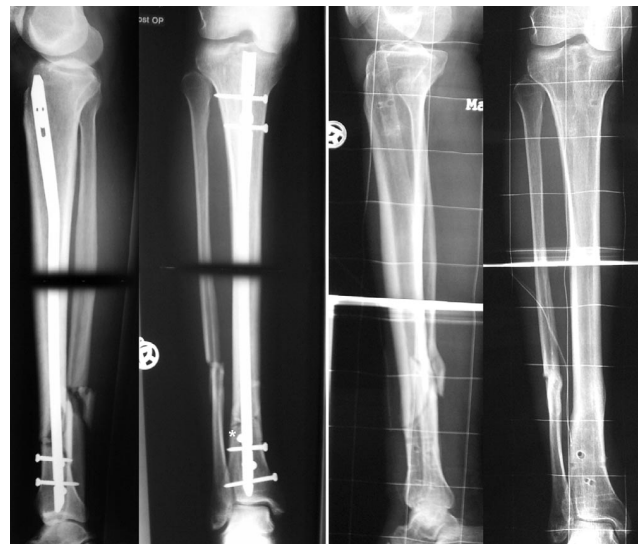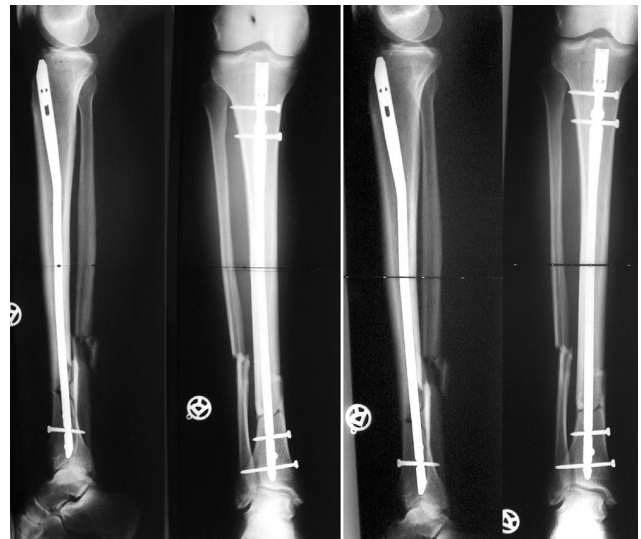
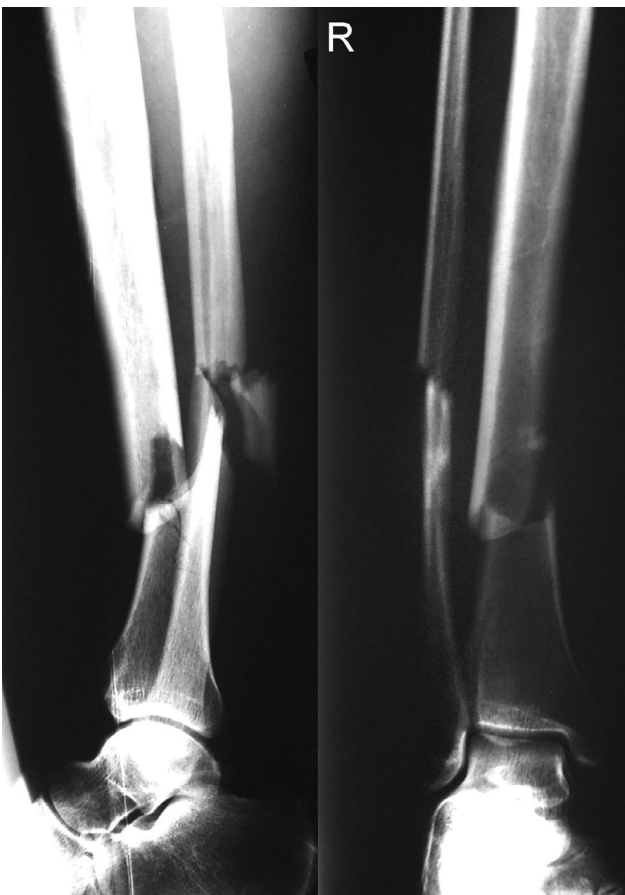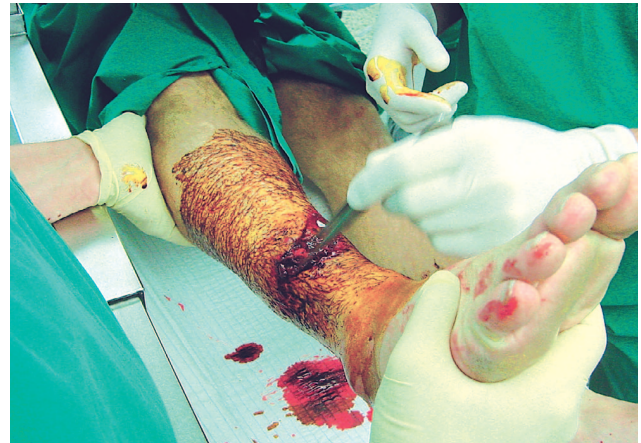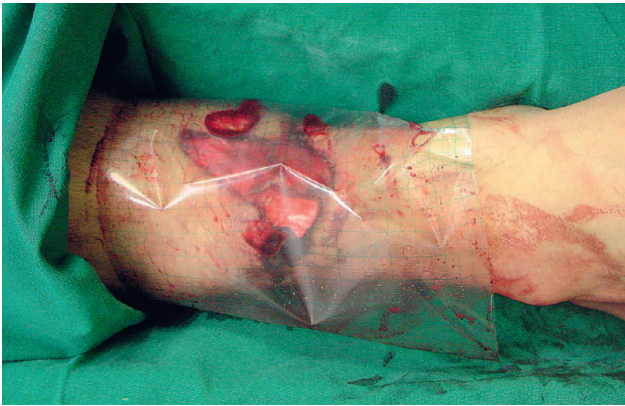


Fig. 2. D. T., m., 49 years, MVA (motorcyclist versus automobile):

- a) Monotrauma: open tibial fracture Gustillo IIIa, covered at the accident site with a sterile folia coverage.  
 b) Radiographs reveal a 43-B1 fracture of the tibia at the diaphyseal border with associated fibular fracture.  
 c) The folia was removed in the operation theatre; after gross inspection and cleaning of the wound the dressings were changed and operative debridement performed. The wound was left open initially and covered with Epigard® skin substitute; after repeated debridements wound closure was achieved 2 weeks after the trauma by secondary suturing.  
 d) Stabilization of the fracture with an unreamed tibial nail (AO – UTN).  
 e) Progressive valgus malalignment of the distal fragment 6 weeks after initial stabilization.

a	c
b	d
f	e
	g

- f+ g) Revision surgery and correction of nail position and alignment with the use of „Poller“ screw (asterix). Further course was uneventful with osseous healing after 10 weeks; nail was removed after 2 years with the patient free of complaints and unlimited occupational and recreational activities.

Table 7. Clinical results of open tibia fractures treated with intramedullary nailing and external fixation

Author	Fracture number	Gustilo classific.		Malalignment	Infection-wound-deep	Inf. surg.-interface	Bone healing (wks)
Henley (29) (1998)	(n=174)	II, IIIa, IIIb	IMN ur*	8 %	13 %	2 %	–
			E. F.	31 %	15 %	50 %	–
Schandelmeier (60) (1997)	(n=41)	IIIb	IMN ur	2/17	1/17	–	31 wks
			E. F.	2/15	2/15	8/15	37 wks
Tornetta (67) (1994)	(n=29)	IIIb	IMN ur	0/15	3/15	0/15	23 wks
			E. F.	2/14	3/14	3/14	28.3 wks
Ostermann (50) (1993)	(n=67)	I-IIIc	IMN ur	–	1/20	–	23.5 wks
			E. F.	–	1/27	–	28.0 wks
Holbrook (32) (1989)	(n=63)	I-III	Ender nail	21 %	7 %	–	5.9 mth
			E. F.	36 %	14 %	21 %	6.6 mth

\* unreamed

results with only 5 % septic complications, when conversion to IMN was performed as early as two weeks after injury. *Schandelmeier et al.* (60) reported in Gustilo IIIb fractures of the tibia the functional impairment due to a reduced mobility of the ankle joint and toes clearly increased in the group of external fixator compared to IMN.

#### Intramedullary nails

Nailing as the golden standard for the treatment of shaft fractures can be also used in open fractures of type I–III (2, 3, 38, 67). *Krettek et al.* (38) evaluated in a meta-analysis of open tibia fractures with 341 UTN stabilizations an over-all infection rate of 4 %–9 %, with 7 %–24 % infections in grade G III fractures. In comparison to external fixation no significant difference can be found in the time required for bone healing and in the rate of deep infection (Table 7). However, *Bhandari et al.* (1) reported in a survey of randomised studies with 396 patients and open tibia fractures a significant lower incidence of reoperations, superficial infections and malunions when the treatment consisted of unreamed nails.

Though experimental evidence exists, that unreamed nailing results in less endosteal vascular compromise than reamed procedures, prospective randomized studies comparing both nailing techniques did not show a significant difference in infection rates (14, 34). In centers of experts adequate infection rates can be achieved with reamed nailing even in most severe fractures of grade G III and development of deep infection seems to be more influenced by the quality of soft tissue treatment than the nailing technique (8).

#### Plates

Plates are used in open fractures of periarticular and metaphyseal location, as well as frequently in the forearm. The results of classic ORIF procedures with plates in open tibial fractures of Grade III are unsatisfactory with infection rates of 45 %–50 % (7, 61). However,

compared to IMN plate fixation does not disturb the endosteal vascularity and provides more stability in metaphyseal areas (13) (Fig. 1 and 2). In contrast to E. F. plates provide full access to the wound without the risk of pintrack infection or malalignment. The development of new plate/screw-systems with the possibility of angular stability offers new options in fracture treatment (18, 71), especially when used as an “internal fixator” (54). These internal fixator are prone to minimal invasive techniques and require no compression of the implant onto the bone for fixation. These factors as well as the biomechanical advantage of relative stability allow rapid secondary bone healing with callus formation. In contrast to external fixation a better acceptance by the patient and facilitated nursing is provided as the fixator is submerged beneath the skin (54, 71).

#### Soft tissue reconstruction and definitive wound closure

In the majority of open fractures primary closure of the skin will increase the risk of infection due to tension at the wound site and local vascular compromise. *Russell et al.* (59) reported deep infection rates after primary wound closure of 20 % compared to 3 % when the wound was initially left open. On the other hand an adequate way of soft tissue coverage is required to avoid septic complications from nosocomial contamination (53). Modern artificial skin substitutes (e. g. Epigard®) or vacuum sealing systems (Vacoseal®) provide an adequate temporary wound coverage. Vacuum sealing offers additive effects of protection against secondary contamination and wound drying as well as continuous control of the local wound situation (65). Applied negative pressures of 60–80 kPa seem to induce a positive effect on local vascularity with development of granulation tissues (72). The latter can eventually act in smaller defects as the basis of subsequent soft tissue closure without flaps (16). On the other hand unexperienced surgeons may lose precious time for wound coverage when relying completely on the tissue inducing effect (70), as vacuum sealing may fail due to drainage from



superficial skin lesions and granulation tissues hardly develop on implants, tendons and bones.

However, extensive tissue damage in severe open fractures requires reconstruction with the use of muscle flaps (20, 48, 70). These flaps improve the local vascularity drastically as muscles represent the primary source of the bone's blood supply when the intramedullary vessels are disrupted (41, 56) and thus allow to clear a bigger amount of inoculated bacteriae (43) as well as a higher local concentration of applied antibiotics (35).

Thus, the decision to use flaps for wound coverage and which kind of flaps (local or free, microvascularized flaps) will be influenced by the local situation after initial debridement and the anatomic site. If the bone is covered by vital muscles delayed skin closure can be achieved by continuously expanding the wound edges, secondary sutures or split skin graft. In all other cases flap coverage is required, especially when noble structures, bone and joints or implants are exposed. If a small area of uncovered bone is surrounded by vital muscles, application of local muscle flaps is possible. *Eggl* (13) reported in 63,2 % good results with these flaps even in IIIB fractures of the lower leg, but emphasized the need of radical and repeated debridement to achieve optimal conditions before flap coverage. In doubt a free muscle transfer is preferable, as the condition of local muscles might be deteriorated by the trauma or its sequelae (compartment syndrome!), mirrored in marked higher deep infection rates of rotational flaps in severe osseous trauma (55). Flap coverage at day 0 after the trauma ("emergency flap") represents the ideal of early defect closure but requires optimal logistic conditions with a microsurgical team available through 24 hours (20, 70). However, early flap coverage within one or two weeks (5, 6, 15, 20, 21, 53, 66, 70) offers clear advantages in respect to deep infection rates and osseous union (Table 8). By respecting the basic principles of flap coverage *Wagner, C. et al.* (70) reported success rates in the lower leg of 95 % with local and of 94,8 % with free flaps, respectively.

An attractive alternative in extensive defects represents the primary shortening of the extremity with consecutive osteotomy and callus distraction after wound healing (10, 17, 19, 33, 38). Up to 10 % of the lower leg's length can be shortened without problems but soft tissue and bone defects should be in the same segment to achieve wound coverage without tension (70). When primary maintenance of the original length of the extremity is desired in segmental bone losses of more than 4–6 cm, osteomyocutaneous transplants from the iliac crest or the fibula ("composite flaps") can bring vascularized muscle tissue into the defect (69, 75).

## DIAGNOSIS OF INFECTION

Allmost all infections result from an additive effect of bacterial inoculation with different virulence and an impairment / defect in the defence mechanisms of the host (25). It is still impossible yet to draw a clear bor-

Table 8. Complication rates of early and delayed flap coverage in open tibial fractures

Author	Year	n	Grade according to Gustilo*	Time-limit (average)	Infection rate	
					early coverage	delayed coverage
Byrd (5)	1985	73	III b-c (own classific.)*	15 days	19 %	60 %
Godina (20)	1986	532		72 hours	1.5 %	17.5 %
Caudle (6)	1987	62	III a-c	7 days	8 %	59 %
Fisher (15)	1991	43	III b	10 days	18 %	69.2 %
Gopal (21)	2000	84	III b-c	72 hours	13 %	30 %

der line between a true infection and a simple wound contamination, which can be found in 60 %–70 % (22, 25, 57, 58). At early stages of infection repeated wound assessments still represent the basis of a correct diagnosis as auxilliary laboratory and radiographic evaluations provide most often only unspecific findings. Though abscess formations and soft tissue infections can be detected by radiographic imaging (sonography, CT – scan, MRT) the value is usually limited in open fractures due to sequelae of the preceding surgical interventions, scar formation or inlying implants. MRT cannot evaluate infections within six weeks postoperatively as no discrimination is possible from chronic osteitis and inlying steel implants preclude an MRT investigation of the affected area. *Hansis* defined that a postoperative infection can be assumed when at least one classic symptom of inflammation occurs along with the need of local therapy and a positive evidence of contamination (25). The proof of microbiological contamination requires additional tissue specimen examination as bacteriological smears alone reveal false negative results in about 10 % of all infections (25).

## THERAPY OPTIONS IN INFECTIONS

Especially in open fractures optimal primary treatment represents the best prophylaxis of infection. In an established infection surgical interventions must focus on the radical elimination of the inflammatory topic. In the acute phase this frequently requires only simple procedures similar to the management of the acute injury (radical removal of necrotic tissues, evacuation of hematomas, irrigation of the wound etc.). After thorough debridement further treatment can consist of open or closed wound management. Open wound management provides reliable results as the local situation can be assessed continuously and easily by repeated changes of the covering antiseptic dressings. In recent years the development of packing wound caves with sponges and evacuation of interstitial tissue fluids and bacteria by continuous drainage (vacuum assisted wound closure = VAC systems) gave remarkable results. However, radical primary debridement of the wound is a prerequisite

for vacuum sealing, which is not a substitute for thorough surgical revision (72).

With an inlying implant the osteitis situation becomes more complicated as on one hand an implant surface never gets sterile after micro-organism colonisation (30) and on the other hand implant removal in critical areas like articular lines is problematic. Fracture healing may occur despite an existing infection if stability is provided by an inlying implant, which may be left in situ (8) when an adequate drainage is provided. However, implant removal should be performed early and if there is any evidence of implant loosening, it must be removed immediately and changed to another fixation concept, usually an external fixator. Infections in intramedullary nails respond well to debridement by reaming of the medullary canal after nail removal and applying of gentamycin PMMA beads (49). If there are still radiological signs of osseous union, only the abscess is evacuated and the nail left in situ with administration of antibiotics till full union. After osseous union the nail is removed the bone reamed and antibiotics continued for another 6 weeks (8, 30).

Chronic infections with septic non-union are three times more frequently found in open fractures and correlated to the severity of soft tissue damage (44, 49). They require complex procedures for the treatment of bony defects after radical debridement and/or decortication. In cases of segmental and large osseous defects secondary reconstruction by osteotomy and bone segment transport (10, 17, 33) or the transplantation of vascularized bone grafts (69, 75) may be required. Here the whole complex of repeated debridements and reconstructive surgery, peri-operative physiotherapy and psychotherapy as well as the compliance and environment of the patient is required to obtain a successful outcome. In desperate cases the tactics have to be adapted to the local situation of the extremity and the demands of the patient including secondary amputation.

## CONCLUSION

With the development of new operative and aseptic techniques as well as a deeper understanding of the pathophysiology of fractures with soft tissue compromise the results have been improved during the last decades. The careful handling of soft tissues with radical debridement of all necrotic tissues, the early coverage of soft tissue defects and the osseous stabilization by minimal invasive implants contribute to the avoidance of infections. However new challenges in form of new and aggressive microorganisms (MRSA), the increasing age of patients with poor bone stock and soft tissues in industrialized countries, new forms of recreational and occupational behaviour as well as an increased expeditive attitude in the treatment outcome by the patients will demand the skill and the interdisciplinary understanding of the treating surgeon.

## Literature

1. BHANDARI, M., GUYATT, G. H., SWIONTKOWSKI, M. F., SCHEMITSCH, E. H.: Treatment of open fractures of the shaft of the tibia. *J. Bone Jt Surg.*, 83-B: 62–68, 2001.
2. BLACHUT, P. A., MEEK, R. N., O'BRIEN, P. J.: External fixation and delayed intramedullary nailing of open fractures of the tibia shaft. *J. Bone Jt Surg.*, 72-A: 729–735, 1990.
3. BONATUS, T., OLSON, S. A., LEE, S., CHAPMAN, M. W.: Non-reamed locking intramedullary nailing for open fractures of the tibia. *Clin. Orthop.*, 339: 58–64, 1997.
4. BRUMBACK, R. J., JONES, A. L.: Interobserver agreement in the classification of open fractures of the tibia. *J. Bone Jt Surg.*, 76-A: 1162–1166, 1994.
5. BYRD, H. S., SPICER, Th. E., CIERNEY, G.: Management of open tibial fractures. *Plast. Reconstr. Surg.*, 76: 719–728, 1985.
6. CAUDLE, R. J., STERN, P. J.: Severe open fractures of the tibia. *J. Bone Jt Surg.*, 69-A: 801–807, 1987.
7. CLIFFORD, R. P., BEAUCHAMP, C. G., KELLAM, J. K., TILE, M.: Plate fixation of open fractures of the tibia. *J. Bone Jt Surg.*, 70-B: 644–648, 1988.
8. COURT-BROWN, C. M., KEATING, J. F., McQUEEN, M. M.: Infection after intramedullary nailing of the tibia. *J. Bone Jt Surg.*, 74-B: 770–774, 1992.
9. De BAKEY, M. E., SIMEONE, F. A.: Battle injuries of the arteries in World War II: an analysis of 2471 cases. *Ann. Surg.*, 123: 534–579, 1946.
10. De BASTIANI, G., ALDEGHERI, R., RENZI-BRIVIO, L., TRIVELLA, G. P.: Chondrodiastasis – controlled symmetrical distraction of the epiphyseal plate. *J. Bone Jt Surg.*, 68-B: 550–556, 1986.
11. DeLONG, W. G., BORN, C. T., WIE, S. Y.: Aggressive treatment of 119 open fracture wounds. *J. Trauma*, 46: 1049–1054, 1999.
12. EDWARDS, C. C., SIMMONS, S. C., BROWNER, B. D., WEIGEL, M. C.: Severe open tibial fractures. *Clin. Orthop.*, 230: 98–115, 1988.
13. EGGELI, S., SCHILL, E., HERTEL, R.: Treatment of III B open tibial fractures with early osteosynthesis and local muscle flaps. *Unfallchirurg*, 101: 674–683, 1998.
14. FINKEMEIER, C. G., SCHMIDT, A. H., KYLE, R. F., TEMPLEMAN, D. C., VARECKA, T. F.: A prospective, randomized study of intramedullary nails inserted with and without reaming for the treatment of open and closed fractures of the tibial shaft. *J. Orthop. Trauma*, 14: 187–193, 2000.
15. FISCHER, M. D., GUSTILLO, R. B., VARECKA, T. F.: The timing of flap coverage, bone grafting and intramedullary nailing in patients who have a fracture of the tibial shaft with extensive soft tissue injury. *J. Bone Jt Surg.*, 73-A: 1316–1322, 1991.
16. FLEISCHMANN, W., STRECKER, W., BOMBELLI, M., KINZL, L.: Vacuum sealing in the treatment of soft tissue trauma in open fractures. *Unfallchirurg*, 96: 488–492, 1993.
17. FRANKE, J., SIMON, M., HEIN, G.: Ilizarov's technique in leg lengthening. *Orthopäde*, 21: 197–209, 1992.
18. FRIGG, R., APPENZELLER, A., CHRISTENSEN, R., FRENK, A., GILBERT, S., SCHAVAN, R.: The development of the distal femur Less Invasive Stabilization System. *Injury*, 32 S3: 24–31, 2001.
19. GIEBEL, G.: Resection-debridement with compensatory callus distraction. *Unfallchirurg*, 94: 401–408, 1991.
20. GODINA, M.: Early microsurgical reconstruction of complex trauma of the extremities. *Plast. Reconstr. Surg.*, 78: 285–292, 1986.
21. GOPAL, S., MAJUMDER, S., BATCHELOR, A. G. B., KNIGHT, S. L., De BOER, P., SMITH, R. M.: Fix and flap: the radical orthopaedic and plastic treatment of severe open fractures of the tibia. *J. Bone Jt Surg.*, 82-B: 959–966, 2000.
22. GUSTILLO, R. B., ANDERSON, J. T.: Prevention of infection in the treatment of one thousand and twenty-five open fractures of long bones: retrospective and prospective analyses. *J. Bone Jt Surg.*, 58-A: 453–458, 1976.

23. GUSTILO, R. B., MENDOZA, R. M., WILLIAMS, D. N.: Problems in the management of type III (severe) open fractures. A new classification of type III open fractures. *J. Trauma*, 24: 742–746, 1984.
24. HAMILTON, F. H. (1860): *Traité pratique des fractures et luxations*, par G. Poinot, Paris. In: Povacz, P.: *History of trauma surgery*. Springer 2000.
25. HANSIS, M.: Posttraumatic and postoperative osseous infections—basics, general and therapeutic considerations. *OP-Journal*, 14: 108–110, 1998.
26. HARLEY, B. J., BEAUPRE, L. A., JONES, C. A., SUKHDEEP, K. D., WEBER, D. W.: The effect of time to definitive treatment on the rate of nonunion and infection in open fractures. *J. Orthop. Trauma*, 16: 484–490, 2002.
27. HASSINGER, S. M., HARDING, G., WONGWORAWAT, M. D.: High pressure pulsatile lavage propagates bacteria into soft tissue. *Clin. Orthop.*, 439: 27–31, 2005.
28. HELFET, D. L., HOWEY, T., SANDERS, R., JOHANSEN, K.: Limb salvage versus amputation. *Clin. Orthop.*, 256: 80–86, 1990.
29. HENLEY, M. B., CHAPMAN, J. R., AGEL, J., WHORTON, A. M., SWIONTKOWSKI, M. F.: Treatment of type II, IIIA and IIIB open fractures of the tibial shaft: a prospective comparison of unreamed interlocking intramedullary nails and half-pin external fixators. *J. Orthop. Trauma*, 12: 1–7, 1998.
30. HEPPELT, V., WETZENSEN, A.: Acute osteitis, *OP-Journal*, 21: 224–230, 2005.
31. HERTEL, R., LAMBERT, S. M., MÜLLER, S., BALLMER, F. T., GANZ, R.: On the timing of soft-tissue reconstruction for open fractures of the lower leg. *Arch. Orthop. Trauma Surg.*, 119: 7–12, 1999.
32. HOLBROOK, J. L., SWIONTKOWSKI, M. F., SANDERS, R.: Treatment of open fractures of the tibial shaft: ender nailing versus external fixation. *J. Bone Jt Surg.*, 71-A: 1231–1238, 1989.
33. ILIZAROV, G. A., LEDYAEV, V. I.: The replacement of long tubular bone defects by lengthening distraction osteotomy of one of the fragments. *Clin. Orthop.*, 280: 7–10, 1992.
34. KEATING, M. P., O'BRIEN, P. J., BLACHUT, P. A., MEEK, R. N., BROEKHUYSE, H. M.: Locking intramedullary nailing with and without reaming for open fractures of the tibial shaft. *J. Bone Jt Surg.*, 79-A: 334–341, 1997.
35. KETTERL, R. L., STEINAU, H. U., FELLER, A. M., STÜBINGER, B., CLAUDI, B. F.: Aggressive debridement and early soft-tissue coverage in grade III open tibial fractures. *Zbl. Chir.*, 115: 209–218, 1990.
36. KHATOD, M., BOTTE, M. J., HOYT, D. B.: Outcomes in open tibia fractures: relationship between delay in treatment and infection. *J. Trauma*, 55: 949–954, 2003.
37. KINDSFATER, K., JONASSEN, E. A.: Osteomyelitis in grade II and III open tibia fractures with late debridement. *J. Orthop. Trauma*, 9: 121–127, 1995.
38. KRETTEK, C., GLÜER, S., SCHANDELMEIER, P., TSCHERNE, H.: Nailing of open fractures. *Orthopäde*, 25: 223–233, 1996.
39. LANGE, R. H., BACH, A. W., HANSEN, S. T., JOHANSEN, K. H.: Open tibial fractures with associated vascular injuries: prognosis for limb salvage. *J. Trauma*, 25: 203–208, 1985.
40. LEE, J.: Efficacy of cultures in the management of open fractures. *Clin. Orthop.*, 339: 71–75, 1997.
41. MacNAB, I., De HAAS, W. G.: The role of periosteal blood supply in the healing of fractures of the tibia. *Clin. Orthop.*, 105: 27–33, 1974.
42. MALGAIGNE, J. F. (1847): *Traité des fractures et des luxations* Baillière, Paris. In: Povacz, P.: *History of trauma surgery*. Springer 2000.
43. MATHES, S. J., ALPERT, B. S., CHANG, N.: Use of the muscle flap in chronic osteomyelitis: experimental and clinical correlation. *Plast. Reconstr. Surg.*, 69: 815–828, 1982.
44. MCGRAW, J. M., LIM, EVA: Treatment of open tibial shaft fractures. External fixation and secondary intramedullary nailing. *J. Bone Jt Surg.*, 70-A: 900–911, 1988.
45. MERITT, PhD.: Factors increasing the risk of infection in patients with open fractures. *J. Trauma*, 28: 823–827, 1988.
46. MOEHRING, H. D., GRAVEL, C., CHAPMAN, M. W., OLSON, S. A.: Comparison of antibiotic beads and intravenous antibiotics in open fractures. *Clin. Orthop.*, 372: 254–261, 2000.
47. MUHR, G., OSTERMANN, P. A.: Treatment of contaminated wounds in fractures. *OP-Journal*, 12: 30–34, 1996.
48. MUHR, G.: Therapeutic strategies in fractures with soft tissue damage. *Chirurg*, 62: 361–366, 1991.
49. OCHSNER, P. E.: Prognosis and complications of open fractures. *Helv. chir. Acta*, 59: 129–141, 1992.
50. OSTERMANN, A. W., SELIGSON, D., HENRY, S. L.: Local antibiotic therapy for severe open fractures. A review of 1085 consecutive cases. *J. Bone Jt Surg.*, 77-B: 93–97, 1995.
51. PATZAKIS, M. J., HARVEY, P., IVLER, D.: The role of antibiotics in the management of open fractures. *J. Bone Jt Surg.*, 56-A: 532–541, 1974.
52. PATZAKIS, M. J., WILKINS, J., MOORE, T. M.: Considerations in reducing the infection rate in open tibial fractures. *Clin. Orthop.*, 178: 36–41, 1983.
53. PATZAKIS, M. J., WILKINS, J.: Factors influencing infection rate in open fracture wounds. *Clin. Orthop.*, 243: 36–40, 1989.
54. PERREN, S. M.: Evolution of the internal fixation of long bone fractures. *J. Bone Jt Surg.*, 84-B: 1093–1110, 2002.
55. POLLAK, A. N., MCCARTHY, M. L., BURGESS, A. R.: Short-term wound complications after application of flaps for coverage of traumatic soft-tissue defects about the tibia: The Lower Extremity Assessment Project (LEAP) Study Group. *J. Bone Jt Surg.*, 82-A: 1681–1691, 2000.
56. RHINELANDER, F. W.: Tibial blood supply in relation to fracture healing. *Clin. Orthop.*, 105: 34–81, 1974.
57. ROBINSON, D., ON, E., HADAS, N., HALPERIN, N., HOFMAN, S., BOLDUR, I.: Microbiological flora contaminating open fractures: It's significance in the choice of primary antibiotic agents and the likelihood of deep wound infection. *J. Orthop. Trauma*, 3: 283–286, 1989.
58. ROJCZYK, M., TSCHERNE, H.: The value of preclinical care in open fractures. *Unfallheilkunde*, 85: 72–75, 1982.
59. RUSSELL, G. G., HENDERSON, R., ARNETT, G.: Primary or delayed closure for open tibial fractures. *J. Bone Jt Surg.*, 72-B: 125–128, 1990.
60. SCHANDELMEIER, P., KRETTEK, C., RUDOLF, J., KOHL, A., TSCHERNE, H.: Advantages of unreamed nailing in grade 3B open tibial fractures compared with external fixation. *Unfallchirurg*, 100: 286–293, 1997.
61. SCHREINLECHNER, P.: Frequency of infections after plate osteosynthesis of open cruris fractures. *Hefte z. Unfallheilkunde*, 157: 86–89, 1982.
62. SELIGSON, D., OSTERMANN, PAW, HENRY, S. L., WOLLEY, T.: The management of open fractures associated with arterial injury requiring vascular repair. *J. Trauma*, 37: 938–940, 1994.
63. SUEDEKAMP, N. P.: Soft-tissue injury: pathophysiology and its influence on fracture management, 59–77 in Rüedi, T. P. and Murphy, W. M.: *AO Principles of Fracture Management*. Thieme 2000.
64. SUEDEKAMP, N. P., BARBEY, N., VEUSKENS, A., TEMPKA, A., HAAS, N. P., HOFFMANN, R., TSCHERNE, H.: The incidence of osteitis in open fractures: an analysis of 948 open fractures. *J. Orthop. Trauma*, 5: 473–482, 1993.
65. TAUTENHAHN, J., BÜRGRE, T., LIPPERT, H.: The present state of vacuum sealing. *Chirurg*, 75: 492–497, 2004.
66. TEMPLEMAN, D. C., GULLI, B., TSUKAYAMA, D. T., GUSTILO, R. B.: Update on the management of open fractures of the tibia shaft. *Clin. Orthop.*, 350: 18–25, 1998.
67. TORNETTA, P., BERGMAN, M., WATNIK, N., BERKOWITZ, G.: Treatment of grade IIIB open tibial fractures. *J. Bone Jt Surg.*, 76-B: 13–19, 1994.
68. TSCHERNE, H., OESTERN, H. J.: A new classification of soft-tissue damage in open and closed fractures. *Unfallheilkunde*, 85: 111–115, 1982.
69. TU, Y. K., YEN, C. Y., YEH, W. L., WANG, I. C., WANG, K. C., NENG UENG, S. W.: Reconstruction of posttraumatic long bone defect with free vascularized bone graft. *Acta orthop. scand.*, 72: 359–364, 2001.

70. WAGNER, C., HEPPERT, V., WETZENSEN, A.: Management of soft tissue damage in lower leg injuries. *Akta Traumatologie*, 34: 153–165, 2004.
71. WAGNER, M.: General principles for the clinical use of the LCP. *Injury*, 34 S 2: 31–42, 2003.
72. WEBB, L. X., SCHMIDT, U.: Vacuum therapy for wound management. *Unfallchirurg*, 104: 918–926, 2001.
73. WEITZ-MARSHALL, A. D., BOSSE, M. J.: Timing of closure of open fractures. *J. Amer. Acad. Orthop. Surg.*, 10: 379–384, 2002.
74. WORLOCK, P., SLACK, R., HARVEY, L., MAWHINNERY, R.: The prevention of infection in open fractures: an experimental study of the effect of fracture stability. *Injury*, 25: 31–38, 1994.
75. YAJIMA, H., TAMAI, S., MIZUMOTO, S., INADA, Y.: Vascularized fibular grafts in the treatment of osteomyelitis and infected nonunion. *Clin. Orthop.*, 293: 256–264, 1993.
76. ZALAVRAS, C. G., PATZAKIS, M. J.: Open Fractures: evaluation and management. *J. Amer. Acad. Orthop. Surg.*, 11: 212–219, 2003.

Th. Neubauer,  
Department of Traumatology  
Wilhelminenspital der Stadt Wien  
Moutleartstrasse 37  
1160 – Wien  
Austria

Práce byla přijata 23. 5. 2006.